



The Effects of *Allium Cepa* Linn (Red Onion Juice) Extract on Aluminum Chloride (AlCl₃) Induced Testicular Toxicity And Renal Toxicity On Male Adult Wistar Rats

Augustus Uchenna UGWU^{1*}, Demian Nnabuihe EZEJINDU¹

Department Of Anatomy, Faculty Of Basic Medical Sciences, College Of Health Sciences, Nnamdi Azikiwe University, Nnewi Campus, Anambra State, Nigeria.

*Corresponding Author

Augustus Uchenna UGWU

Department Of Anatomy,
Faculty Of Basic Medical
Sciences, College Of Health
Sciences, Nnamdi Azikiwe
University, Nnewi Campus,
Anambra State, Nigeria.

Article History

Received: 29.03.2024

Accepted: 15.04.2024

Published: 04.05.2024

Abstract: Considerable discussion has arisen over the perilous ramifications of aluminum chloride (AlCl₃) on human health. However, it remains uncertain if the toxicity is associated with vital organs such as testes and kidneys. The aim of this study is to investigate the harmful effects of AlCl₃ on testicles and renal tissues, as well as to evaluate the protective role of *Allium cepa* Linn (AcL) extract over the toxic effects of AlCl₃ on these organs. A total of sixteen adult Wistar rats, weighing between 200 and 240 grams, were placed into four groups, each consisting of four animals. As the control, Group A was provided with standard rat chows and water. Group B got a treatment of 200 mg/kg body weight of AcL extract exclusively, while group C received a treatment of 90 mg/kg body weight of AlCl₃ alone. Group D, on the other hand, received a co-treatment consisting of 90 mg/kg body weight of AlCl₃ combined with 200 mg/kg body weight of AcL extract. Each therapy was administered orally on a daily basis for a duration of 21 days. Animals were anesthetized using chloroform vapor and then dissected twenty-four hours following the last treatment. The testicular and renal tissues were collected, measured, and preserved in a 10% formal saline solution for further histological examination. Serum preparation was conducted by collecting blood by eye puncture in order to facilitate histochemical tests. In group C, there was a substantial drop ($p < 0.05$) in the body and testicular weights of the Wistar rats. Additionally, there was a statistically significant rise ($p < 0.05$) in kidney weights compared to the control group. A statistically significant difference ($p < 0.05$) was seen in the body and organ weights of groups B and D, which was comparable to that of the control group. The study found that there was no significant difference ($p > 0.05$) in motility of sperm, typical sperm morphology, and serum levels of ICSH and testosterone between groups B and C. However, there was a significant difference ($p > 0.05$) in total sperm count and Pus cells between group B and group D, which was similar to the control. The amounts of urea and creatinine were not substantially higher ($p > 0.05$) in group C compared to the control, group B, and group D. Histological examination demonstrated that subsequent to the application of AlCl₃, there was a notable modification in the typical structures of the testes and kidneys. This alteration encompassed significant tissue degeneration, pronounced apoptosis of germinal cells in the testes, and a concentrated accumulation of inflammatory cells resulting from extensive regeneration of renal tissue. Furthermore, the injection of AcL juice extract resulted in a modest restoration of testicular and renal tissue architectures. The study's findings indicate that the treatment of AlCl₃ resulted in testicular and renal toxicity, leading to impaired reproductive and renal functions. Conversely, the administration of *Allium cepa* linn (AcL) extract mitigated the toxicity, therefore safeguarding and improving the testicular and renal structures. The findings of this research indicate that the extract derived from *Allium cepa* Linn (AcL) has therapeutic characteristics in mitigating the toxicity generated by aluminum chloride (AlCl₃).

Keywords: Aluminum Chloride, Testicular Toxicity, *Allium Cepa* Linn, Renal Toxicity, Fertility.

Cite this article:

UGWU, A.U., EZEJINDU, D.N., (2024). The Effects of *Allium Cepa* Linn (Red Onion Juice) Extract On Aluminum Chloride (AlCl₃) Induced Testicular Toxicity And Renal Toxicity On Male Adult Wistar Rats. *ISAR Journal of Medical and Pharmaceutical Sciences*, 2(5), 1-22.

INTRODUCTION

Metals are often encountered by humans. This may be attributed to their widespread presence in nature, contaminated soil, water, air, and food, varied use in industry, and enduring presence in the environment. The male reproductive and renal systems may be significantly impacted by metals, either by direct targeting of particular organs or through indirect effects on the neuroendocrine system. Previous studies have shown the impact of metals on spermatogenesis in both rats and humans, resulting in reduced sperm counts, atypical sperm morphology, and diminished semen quality (Pizent *et al.*, 2012; Verstraeten *et al.*, 2008). Additionally, metals have been found to inhibit renal functions (Mestaghanmi *et al.*, 2002; Stella *et al.*, 2005). Aluminum (Al) is a prominent metal that exhibits a broad distribution as a trivalent cation. It is often found in its ionic form in many animal and plant tissues, as well as in natural water sources around the globe. According to ATSDR (2008), titanium is the third most common component and the most plentiful metal in the outermost layer of the earth, accounting for roughly 8% of the total mineral components.

Aluminum is found in the natural environment and is also emitted as a result of human activity, including mining and industrial processes involved in the manufacturing of aluminum metal and other aluminum compounds. According to Salama *et al.* (2009), a diverse range of aluminum compounds are manufactured and used for many applications, including but not limited to water purification, paper production, fire retardant properties, filler materials, food additives, colorants, and medicines. Aluminium, primarily in the form of metal alloys, has several applications, such as in consumer appliances, food packaging, and cookware (EFSA, 2008). Aluminum has always been regarded as an element with little toxicological implications, and its entry into the human body occurs via the gastrointestinal and respiratory systems (Verstraeten *et al.*, 2008). While aluminum is found in trace levels in biological substances, it is not considered a vital element and is generally regarded as having detrimental impacts on overall health (ATSDR, 2008). According to Alferey *et al.* (1976) and Abbasali *et al.* (2005), aluminum chloride (AlCl₃) is recognized as a neurotoxic with the potential to induce several disorders, including Alzheimer's disease, dialysis-induced dementia, Parkinsonism, and amyotrophic lateral sclerosis. Apart from its neurotoxic effects, Al also has an impact on other physiological components such as the kidney, liver, brain tissue, bone, blood cells, and skeletal system (Mestaghanmi *et al.*, 2002; Stella *et al.*, 2005). Corn, yellow cheese, salt, herbs, spices, tea, cosmetics, aluminumware, and containers are the primary sources of aluminum. According to Pizent *et al.* (2012), aluminum is extensively used in antacid medications, food additives, and toothpaste. The presence of various aluminum-containing compounds in environmental pollution, particularly in industrial wastewater, results in elevated levels of aluminum exposure for individuals (Kloppel *et al.*, 1976). AlCl₃ has been identified as an environmental constituent that has the potential to induce cytotoxicity via free radicals, therefore affecting several enzymes and other biomolecules, and perhaps playing a role in certain illnesses. Numerous studies done on laboratory animals have provided evidence indicating that aluminum induces reproductive toxicity and has a significant adverse influence on steroidogenesis. (Yousef *et al.*, 2009). There exists a correlation between the buildup of aluminum and the occurrence of sperm cell necrosis and infertility. Alessio *et al.* (1989) found that increased levels of aluminum in the blood of

mine workers resulted in a decrease in prolactin and thyroid stimulating hormone. Previous research has shown that aluminum has the ability to inhibit voltage-gated calcium channels (Busselberg *et al.*, 1994), leading to a decrease in gonadotrophin production in the hypophysis (Mills *et al.*, 1994). Consequently, this impairment results in reduced sperm counts (Llobet *et al.*, 1994). Several studies have shown that aluminum has the potential to decrease antioxidant activity (Yousef *et al.*, 2009) and promote lipid peroxidation (Anane *et al.*, 2001). According to Gonzalez *et al.* (2007), there have been reports indicating that aluminum (Al) has the potential to induce degeneration in renal tubular cells by generating reactive oxygen species (ROS). These ROS may lead to oxidative damage in cellular lipids, proteins, and DNAs. The investigation of the mechanisms behind aluminum-induced testicular toxicity and renal toxicity, as well as the development of efficacious treatments for these deficiencies, have significant relevance and must be prioritized by both industrialized and developing countries.

Allium cepa linn (red onions) has gained widespread agreement in recent years for its beneficial effects in preventing and treating various diseases. This is attributed to its strong anti-inflammatory, anti-carcinogenic, hypolipidemic, anti-thrombotic, anti-asthmatic, antibacterial, and anti-fungal antioxidant properties (Griffiths *et al.*, 2002). *Allium cepa* linn, a plant belonging to the Liliaceae family, has been extensively used for both culinary and medicinal applications for an extended period. Onions, such as *Allium cepa* Linn, are believed to provide advantageous properties for human health due to their high content of chemicals. Several commercially marketed cultivars of *Allium cepa* exhibit variations in plant-based constituents and biological activity. Numerous studies have shown that the extract derived from *Allium cepa* linn has both exogenous and endogenous antioxidants, including selenium, glutathione and vitamins A, B, and C, as well as flavonoids such as quercetin and isorhamnetin.

The research conducted by Ige *et al.* (2011), Guercio *et al.* (2014), and Kumar *et al.* (2016) has shown a correlation between the antioxidant properties of *Allium cepa* linn and a decrease in lipid peroxidation index, malondialdehyde (MDA), and an increase in superoxide dismutase (SOD). Additionally, it serves to safeguard DNA and other crucial components from oxidative harm, potentially enhancing sperm health metrics and augmenting male fertility rates (Rajeev and Narmada, 2006; Yang *et al.*, 2006). The extract and chemical components of *Allium cepa* linn exhibit a wide range of pharmacological actions, with a particular emphasis on their capacity to scavenge free radicals. These effects serve to safeguard against oxidative damage by modulating intracellular signals and facilitating cell survival (Dai *et al.*, 2013). According to Guercio *et al.* (2014), recent epidemiological data presents strong evidence supporting the notion that the intake of onions is associated with a decreased risk of stomach cancer. Ige and Akhigbe (2012) have shown in prior research that *Allium cepa* has antagonistic properties against the harmful effects of aluminum chloride (AlCl₃), while concurrently enhancing the antioxidant status and sperm quality in male rats.

In the scrotum, the testes are a pair of egg-shaped organs that are hung by the spermatic cord. According to Carrau *et al.* (2002), these entities exhibit two primary roles: the synthesis of steroid hormones and the generation of spermatozoa. The typical dimensions of a testicular length are around 4-5cm, 2.5cm in

width, and 3cm in thickness. The weight of the testes exhibits age-related variations, with the left testis typically positioned inferior to the right testis (Gray, 2005). The kidneys play a crucial role in the regulation of electrolyte balance in the bloodstream, as well as the maintenance of acid-base homeostasis (Sembulingam, 2012).

In addition, they facilitate the elimination of waste substances from the bloodstream and their excretion in the urine, including nitrogenous urea and ammonium. The kidneys also maintain fluid equilibrium and control blood pressure. Additionally, they are accountable for the process of reabsorption pertaining to water, glucose, and amino acids. According to Sembulingam (2012), the kidneys are responsible for the synthesis of several hormones, such as calcitriol and erythropoietin. The kidneys are responsible for the synthesis of rennin, a crucial enzyme that exerts its influence on blood pressure via a negative feedback process. The kidneys are situated in the retroperitoneal area, namely in the posterior region of the abdominal cavity. They receive blood from the paired renal arteries and then empty into the paired renal veins. Nephrology is the scientific and medical study of kidney disorders, while renal physiology focuses on the study of kidney function. There exists a wide range of renal diseases, one of which may be attributed to the administration of AlCl₃ and other harmful compounds (Staghanmi *et al.*, 2002; Stella *et al.*, 2005). Based on the aforementioned observations and potential modes of action of AlCl₃, it is therefore postulated that the extract of *Allium cepa* linn may possess a protective effect against testicular and renal damage generated by aluminum chloride (AlCl₃). The primary objective of this research is to document the putative protective properties of *Allium cepa* linn against testicular and renal toxicities produced by aluminum chloride (AlCl₃).

MATERIALS AND METHODS

LOCATION AND DURATION OF THE STUDY

This study was carried out in the Department of Anatomy, Nnamdi Azikiwe University, Nnewi Campus, Anambra State, Nigeria. The rats were acclimatized for a period of two weeks, after which the test substances were administered for 21 days. Hence, the entire experiment lasted for about five weeks.

ETHICAL APPROVAL

The research ethics committee of the Faculty of Basic Medical Sciences, College of Health Sciences, Nnamdi Azikiwe University Nnewi Campus, approved this work.

EXPERIMENTAL PROTOCOL

The aluminum chloride (AlCl₃) was purchased from the biochemistry lab in the Department of Biochemistry, Nnamdi Azikiwe University, Nnewi Campus. *T. allium cepa* was randomly purchased from the market and identified at the herbarium of the Department of Botany, Nnamdi Azikiwe University, Awka, Anambra State. The botanical identification and authentication were done at the Botany Department, Faculty of Agriculture, Nnamdi Azikiwe University Awka, Anambra State. The feed that was used was normal grower mesh produce.

The study was conducted using a sample of twenty (20) male adult albino Wistar rats, with weights ranging from 200 to 240 g. The rodents were obtained from a nearby agricultural establishment in Nnewi and relocated to the experimental location. The subjects were categorized into four groups (A to D) and accommodated in four conventional enclosures. An analytical weighing scale was used to quantify the weight of each rat. The subjects were provided with nourishment and hydration for a duration of fourteen days in order to facilitate their adaptation to the novel surroundings prior to the commencement of the experiment. During the time of acclimation, the rats were provided with a diet consisting of regular rats' chows with a known weight of around 100g, along with daily water intake. The control group was designated as Group A, whilst the experimental groups were designated as Groups B, C, and D.

EXTRACTION OF THE ORGANS AND COLLECTION OF SAMPLES

After the rats were given the medication for 21 days, they were euthanized. The kidneys and testicles were then removed and preserved in normal saline to preserve their physiological state. Finally, they were weighed and fixed in 10% formal saline for histological processing.

HISTOLOGICAL PROCEDURES/TISSUE PROCESSING:

After determining the weight of the organs, a small section of the kidney and testicular tissues will be extracted. These tissues will then be promptly immersed in 10% formal saline solution to avoid autolysis and putrefaction, while also preserving the normal microanatomical locations of the different cell components. Tissue sections will be produced using typical histochemical processes such as fixation, dehydration, clearing, impregnation, embedding, sectioning, and staining (using H and E). The last step involves use a light microscope to capture micrographs of the relevant stained sections.

STATISTICAL ANALYSIS

The data that will be obtained will be analyzed using the statistical package for social sciences (SPSS) version 20.0, and the result will be expressed as mean \pm standard error of mean (SEM). Significant differences in the results will be established by one-way analysis of variance (ANOVA), and the acceptance level of significance will be $p < 0.05$ for all the results.

RESULTS

PHYSICAL AND BEHAVIOURAL CHANGES

All of the rats grew big and were in good health during the acclimation period. They had pink eyes, skin that was typical in color, and neatly laid hairs on their skin. Following the start of the experiment, group A, the control group, did not exhibit signs or symptoms. After receiving *Allium cepa* linn juice, group B had significant growth in both size and weight, as well as an increased demand for food. Following administration of AlCl₃, group C exhibited significant labor breathing, stumbling, and reduced meal intake. In contrast, group D (which received AlCl₃ and AlCl₃ extract) displayed a modest rise in food intake along with a significant increase in weight and body size.

BODY WEIGHT CHANGES.

TABLE 4.2.1 Shows the effect of *Allium cepa linn*(red onion juice)Extract on AlCl3 induced the body weight of male Wistar rats.

Body weight changes(g)		MEAN±SEM	P-VALUE	T-VALUE
Group A	Initial	210.00±0.00		
	Final	245.00±5.00	0.010*	-7.000
Group B	Initial	230.00±10.00		
	Final	280.00±10.00	0.036*	-3.536
Group C	Initial	230.00±10.00		
	Final	195.00±5.00	0.045*	3.130
Group D	Initial	205.00±5.00		
	Final	255.00±5.00	0.010*	-7.071

Data were analyzed using Student Independent T-test and values were considered significant at P<0.05. *P<0.05 means significant.

The results from the table above showed that there was a significant increase in body weight when comparing the initial body weight (210.00±0.00) to the final weight (245.00±5.00) in group A. In group B, there was a significant increase in body weight when comparing the initial body weight (230.00±10.00) to the final weight (280.00±10.00). For group C, there was a significant decrease in body weight when comparing the initial weight (230.00±10.00) to the final weight (195.00±5.00). For group D, there was a significant increase in body weight when comparing the initial body weight (205.00±5.00) to the final weight (255.00±11.81).

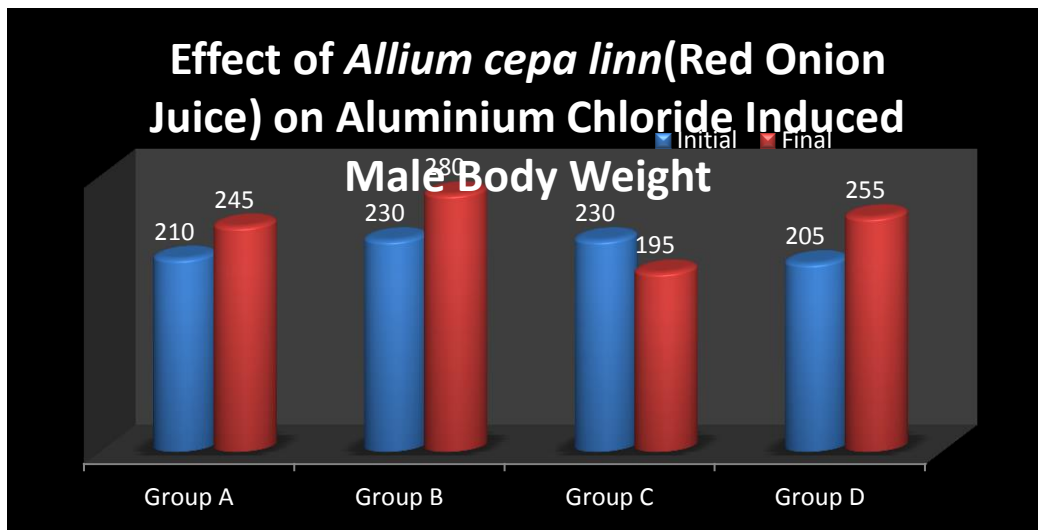


Fig 4.1 Bar chart showing the Effect of *Allium cepa linn*(red onion juice) on AlCl3 induced Body weight of male Wistar rats

4.3.0 ORGAN WEIGHT CHANGES

TABLE 4.2 Showing the effect of *Allium cepa linn*(red onion juice) extract on AlCl3 induced Relative Testicular weight and kidney weight of male Wistar Rats

			MEAN±SEM	P-VALUE	F-VALUE
Relative testicular weight	Group A		4.57±0.01	_____	
	Group B		4.97±0.01	0.012*	
	Group C		4.40±0.05	0.001*	
	Group D		4.53±0.04	0.002*	70.330
Relative kidney weight	Group A		2.34±0.08	_____	
	Group B		2.35±0.03	0.001*	
	Group C		2.70±0.01	0.021*	
	Group D		2.28±0.11	0.160	24.067

Data were analyzed using One way ANOVA followed by Post HOC Fisher’s LSD multiple comparism, and data were considered significant at P<0.05. *P<0.05 means significant and P>0.05 means not significant.

The results from the table above showed a statistically significant difference in the relative testicular weight in groups B (4.97 ± 0.01) and D (4.43 ± 0.04), similar to group A (4.57 ± 0.01), while there was a statistically significant decrease in group C (4.40 ± 0.05) when compared to the control. The result for relative kidney weight showed a significant increase in group C (2.70 ± 0.01), an insignificant difference in group D (2.28 ± 0.11), and a statistically significant difference in group B (2.35 ± 0.03), similar to group A (2.34 ± 0.08).

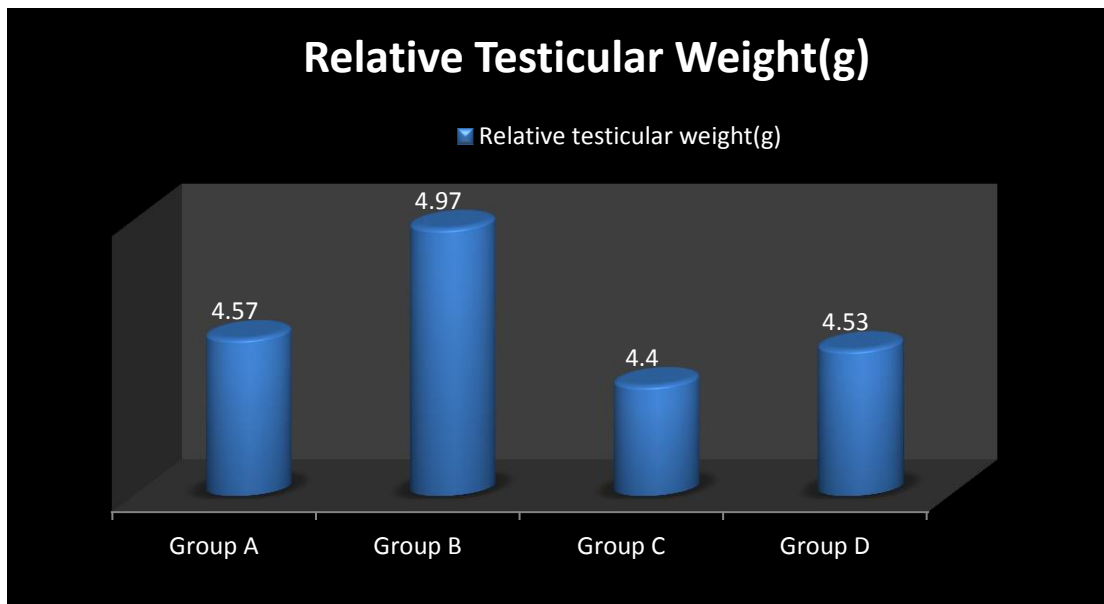


Fig 4.2 Bar chart showing the Effect of *Allium cepa linn*(red onion juice) on AICl3 induced Relative testicular weight of male Wistar rats

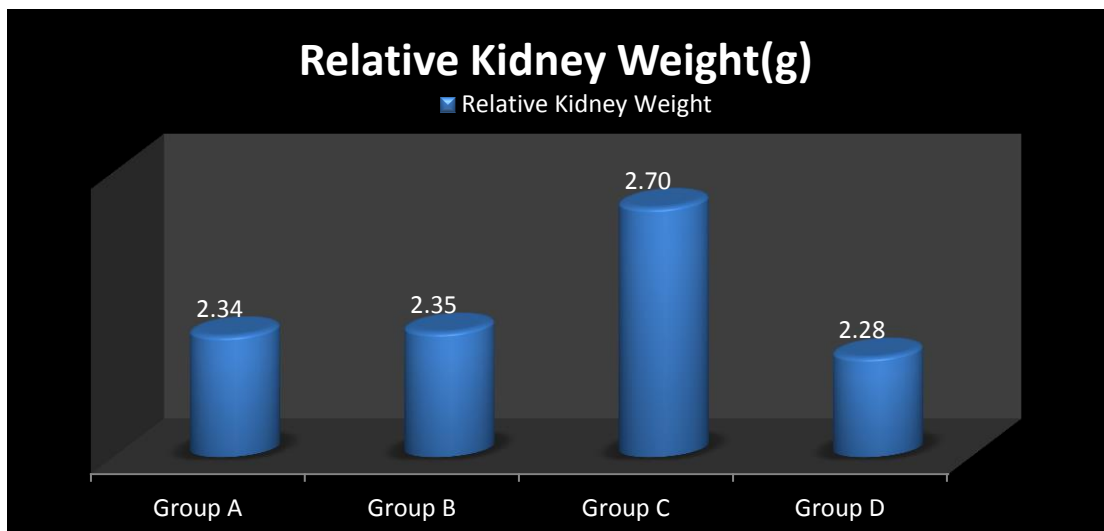


Fig 4.3 Bar chart showing the Effect of *Allium cepa linn* (red onion juice) on AICl3 induced Relative kidney weight of male Wistar rats

4.4.0 SEMEN ANALYSIS

TABLE 4.3: Showing the effect of *Allium cepa linn* (red onion juice) extract on AICl3 induced Sperm motility and sperm count of male Wistar Rats

		MEAN±SEM	P-VALUE	F-VALUE
Sperm Motility (%)	Group A	77.50±2.50	_____	
	Group B	85.00±0.00	0.320	0.857
	Group C	75.00±5.00	0.725	
	Group D	77.50±7.50	1.000	
Total Sperm Count(x10 ⁶)	Group A	400.00±80.00	_____	
	Group B	595.00±25.00	0.039*	6.582
	Group C	335.00±25.00	0.371	
	Group D	366±26.00	0.626	

Data were analyzed using One way ANOVA followed by Post HOC Fisher's LSD multiple comparison, and data were considered significant at $P < 0.05$. $*P < 0.05$ means significant and $P > 0.05$ means not significant.

The results from the table above showed an insignificant increase in sperm motility in group B (85.00 ± 0.00), an insignificant ($P > 0.05$) decrease in group C (75.00 ± 5.00), and no significant mean difference in group D (77.50 ± 7.50) when compared to group A (77.50 ± 2.50). There was a statistically significant ($*P < 0.05$) increase in the total sperm count in group B (595.00 ± 25.00) and an insignificant difference in group D (366.00 ± 26.00) similar to the control. Also, an insignificant decrease in group C (335.00 ± 25.00) occurred when compared to group A (400.00 ± 80.00).

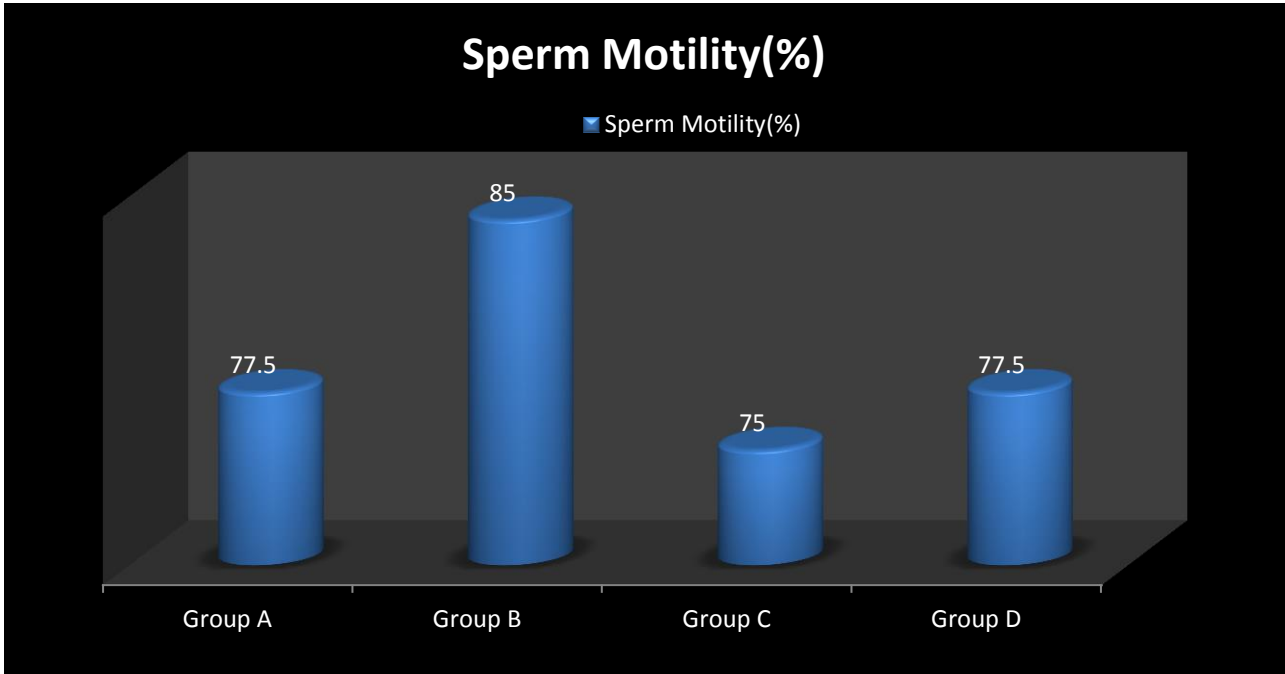


Fig 4.4 Bar chart showing the Effect of *Allium cepa linn*(red onion juice) on AICl3 induced Sperm motility of male Wistar rats.

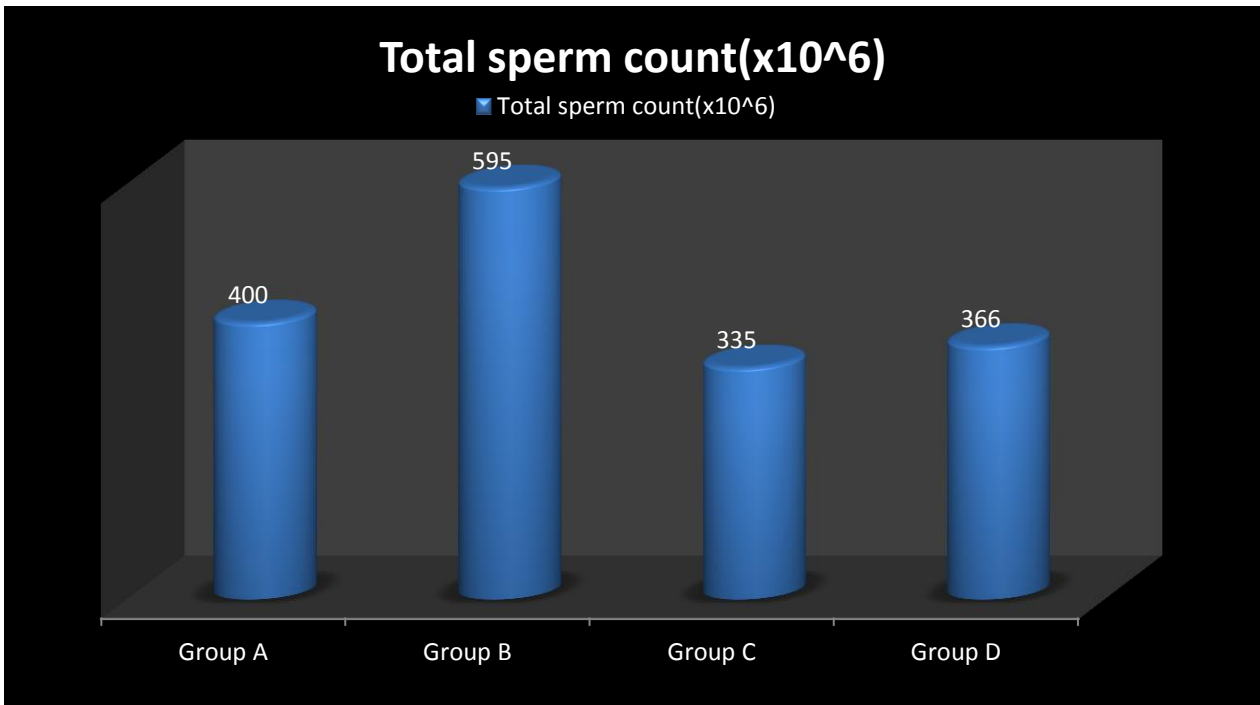


Fig 4.5 Bar chart showing the Effect of *Allium cepa linn*(red onion juice) on AICl3 induced Sperm motility of male Wistar rats.

TABLE 4.4 Showing the effect of *Allium cepa linn*(red onion juice) extract on AlCl3 induced Sperm morphology of male Wistar Rats.

SPERM MORPHOLOGY(%)		MEAN±SEM	P-VALUE	F-VALUE
Normal	Group A	86.50±1.50	_____	1.282
	Group B	87.50±2.50	0.731	
	Group C	82.50±2.50	0.215	
	Group D	85.00±0.00	0.610	
Abnormal	Group A	13.50±1.50	_____	1.282
	Group B	12.50±2.50	0.215	
	Group C	17.50±2.50	0.215	
	Group D	15.00±0.00	0.610	
Pus cells	Group A	1.00±0.00	_____	4.000
	Group B	0.50±0.707	0.040*	
	Group C	2.00±0.00	0.116	
	Group D	0.50±0.50	0.040*	

Data were analyzed using One way ANOVA followed by Post HOC Fisher’s LSD multiple comparism, and data were considered significant at P<0.05. *P<0.05 means significant and P>0.05 means not significant.

The results from the table above showed that normal sperm morphology in group C insignificantly (P > 0.05) decreased, while there were insignificant (P > 0.05) differences in groups B and D when similar to group A (86.50±1.50). Abnormal sperm morphology in groups B and D decreased insignificantly (P<0.05), while there was an insignificant (P>0.05) increase in group C when compared to group A (13.50±1.50). There was a significant (P<0.05) decrease of pus cells in groups B and D, while there was an insignificant (P>0.05) increase in group C when compared to group A (1.00±0.00).

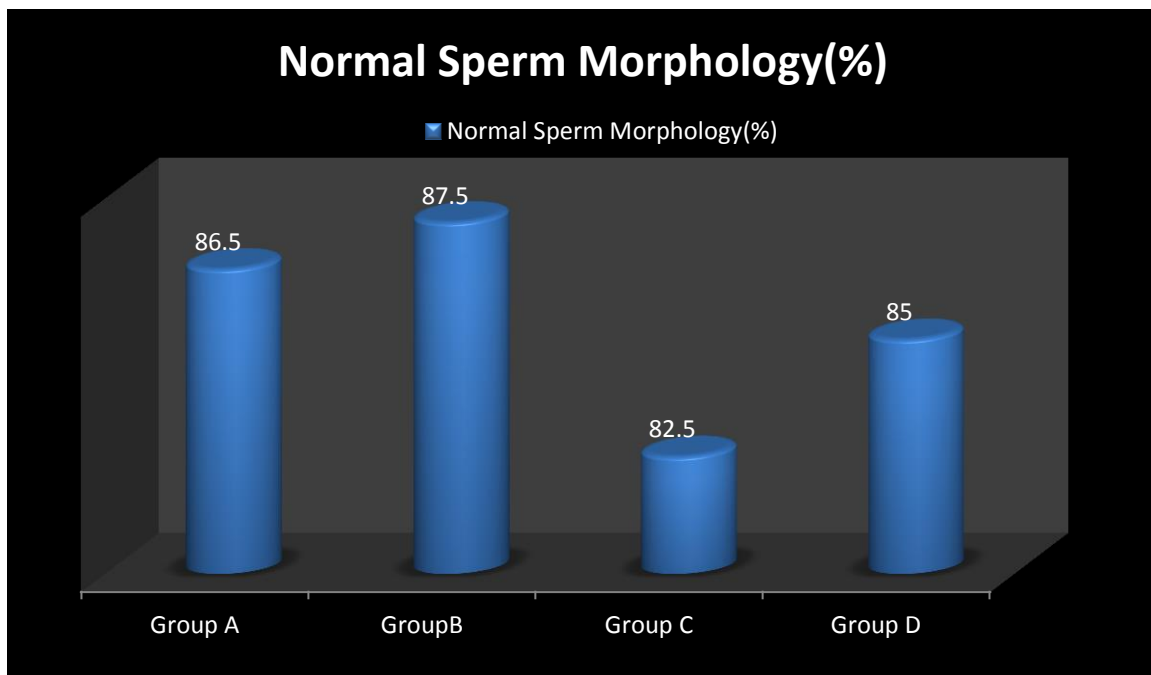


Fig 4.6 Bar chart showing the Effect of *Allium cepa linn*(red onion juice) on AlCl3 induced Normal Sperm morphology of male Wistar rats

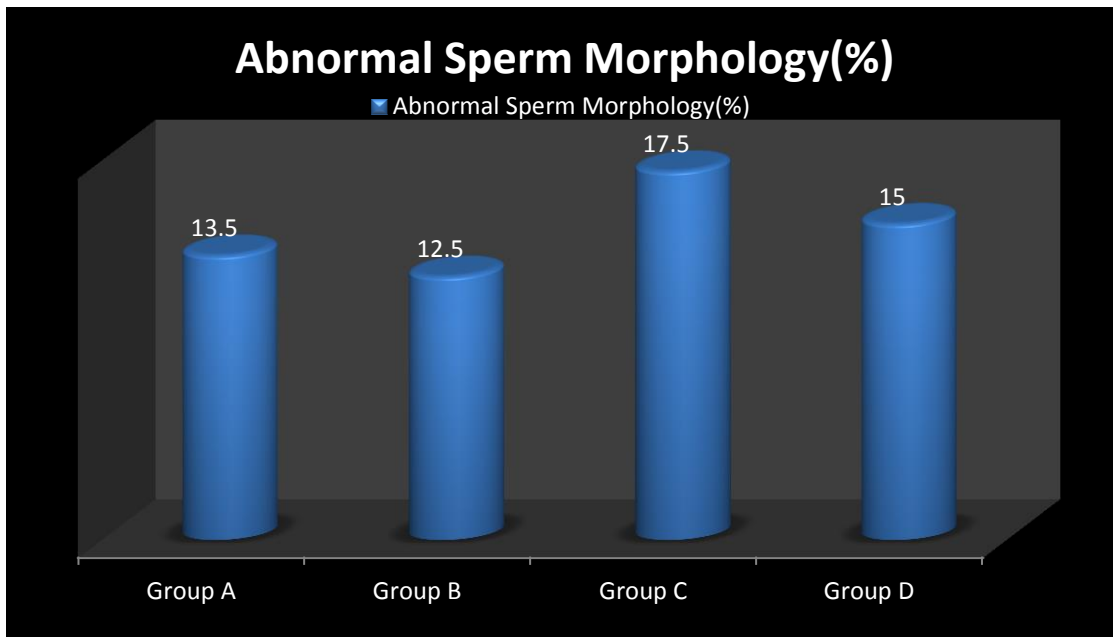


Fig 4.7 Bar chart showing the Effect of *Allium cepa linn*(red onion juice) on AICI3 induced Abnormal Sperm morphology of male Wistar rats.

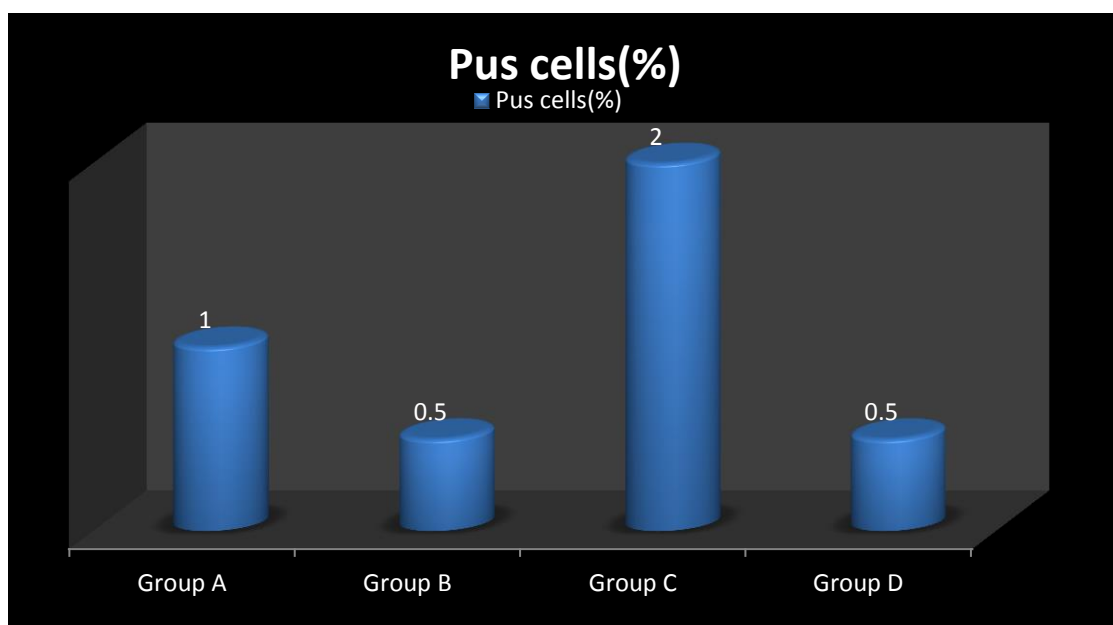


Fig 4.8 Bar chart showing the Effect of *Allium cepa linn*(red onion juice) on AICI3 induced Pus Cells of male Wistar rats.

4.5.0 ACTIVITIES OF SERUM LEVELS OF TESTOSTERONE AND INTERSTITIALCELL STIMULATING HORMONE(ICSH).

TABLE 4.5: Showing the effect of *Allium cepa linn*(Red onion juice) extract on AICI3 induced hormonal levels of male Wistar Rats

			MEAN±SEM	P-VALUE	F-VALUE
Interstitial Stimulating Hormones(ICSH) (ng/ml)	Cells	Group A	7.15±1.35	_____	0.585
		Group B	7.25±0.25	0.864	
		Group C	5.95±0.56	0.334	
		Group D	6.75±0.45	0.505	
Testosterone(ng/ml)		Group A	5.30±0.90	_____	0.044
		Group B	6.15±0.55	0.212	
		Group C	4.15±0.55	0.244	
		Group D	5.05±0.05	0.239	

Data were analyzed using One way ANOVA followed by Post HOC Fisher's LSD multiple comparison, and data were considered significant at $P < 0.05$. $*P < 0.05$ means significant and $P > 0.05$ means not significant.

The results from the table above showed an insignificant ($P > 0.05$) increase in ICSH concentration in groups B and D, while there was an insignificant decrease in group C when compared to group A (7.15 ± 1.35). There was also an insignificant ($P > 0.05$) increase and decrease of testosterone concentration in groups B and C, respectively, and a statistically significant ($*P < 0.05$) increase in group D when compared to group A (5.30 ± 0.90).

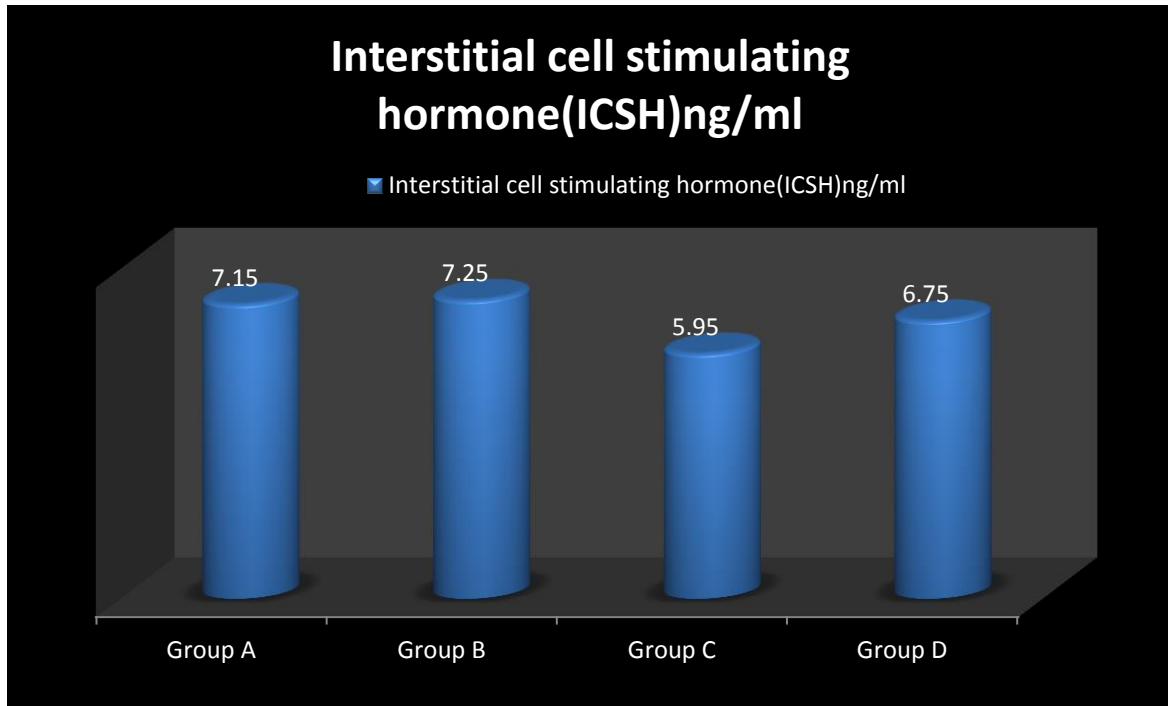


Fig 4.9: Bar chart showing the Effect of *Allium cepa linn*(red onion juice) on AICI3 induced serum Interstitial Cell Stimulating Hormone(ICSH) assay of male Wistar rats.

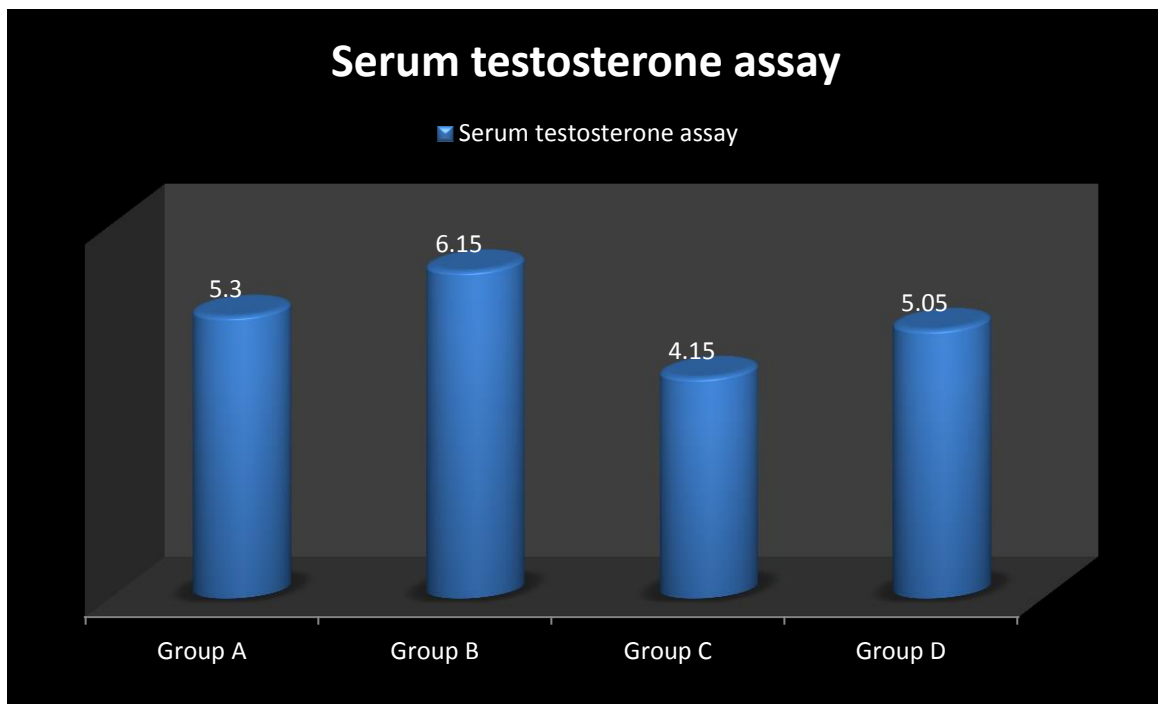


Fig 4.10: Bar chart showing the Effect of *Allium cepa linn*(red onion juice) on AICI3 induced serum testosterone assay of male Wistar rats.

4.6.0 ACTIVITIES OF SERUM LEVELS OF UREA AND CREATININE CONCENTRATIONS

TABLE 4.6: Showing the effect of *Allium cepa* linn(red onion juice) extract on AlCl3 induced kidney function of male Wistar Rats.

KIDNEY FUNCTION TEST		MEAN±SEM	P-VALUE	T-VALUE
Urea concentration(mg/dL)	Group A	7.05±0.25	_____	1.003
	Group B	6.40±0.30	0.688	
	Group C	7.25±2.05	0.901	
	Group D	6.90±0.40	0.226	
Creatinine Concentration(mg/dL)	Group A	34.00±1.00	_____	2.060
	Group B	38.00±4.00	0.474	
	Group C	49.50±5.50	0.086	
	Group D	43.00±2.00	0.150	

One way ANOVA was used to evaluate the data, and Post HOC Fisher's LSD multiple comparism was used to determine significance (P<0.05). *P>0.05 indicates not significant, while *P<0.05 indicates significant.

The results from the table above showed an insignificant decrease in urea concentration in groups B (6.40±0.30) and D (4.90±0.40), while there was an insignificant increase in group C (7.25±2.05) when compared to group A (7.05±0.25). There was also an insignificant increase in creatinine concentration, higher in group C (49.50±5.50) than in groups A (34.00±1.00), B (38.00±4.00), and D (43.00±2.00).

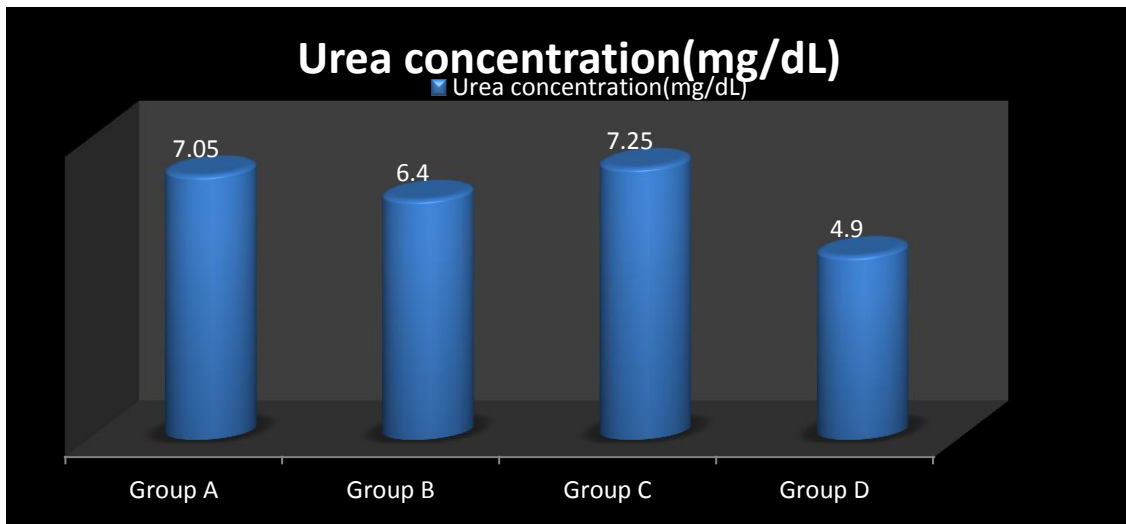


Fig 4.11: Bar chart showing the Effect of *Allium cepa linn*(red onion juice) on AlCl3 induced Urea concentration of male Wistar rats

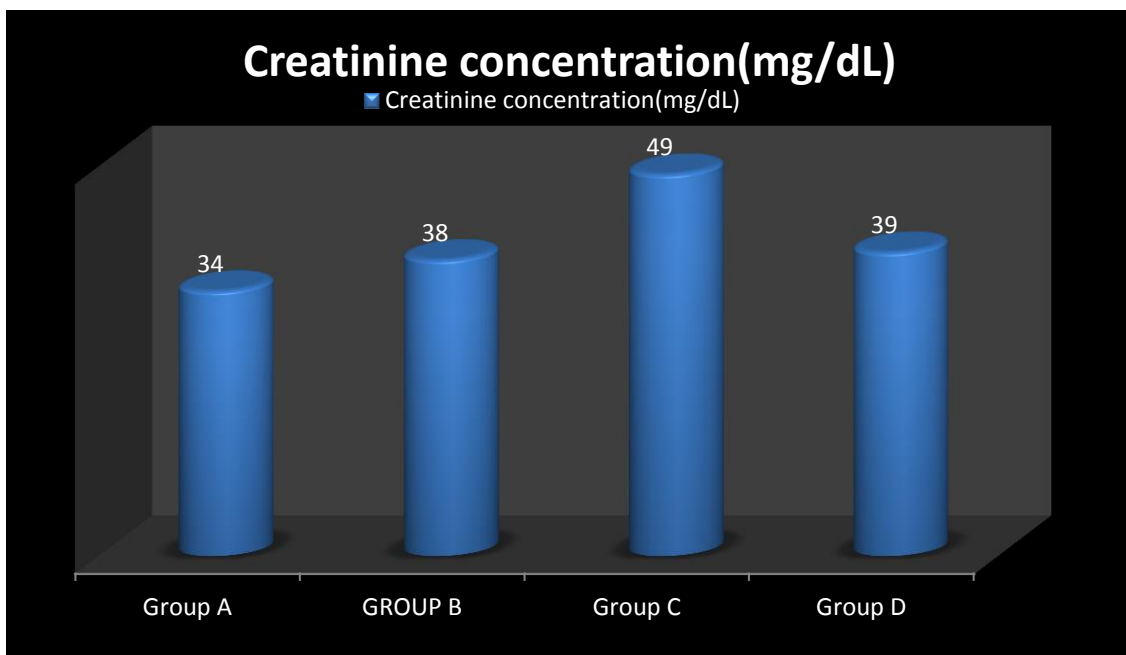


Fig 4.11: Bar chart showing the Effect of *Allium cepa linn*(red onion juice) on AlCl3 induced Creatinine concentration of male Wistar rats.

4.7.0 HISTOPATHOLOGICAL FINDINGS

PHOTOMICROGRAPH OF THE TESTIS

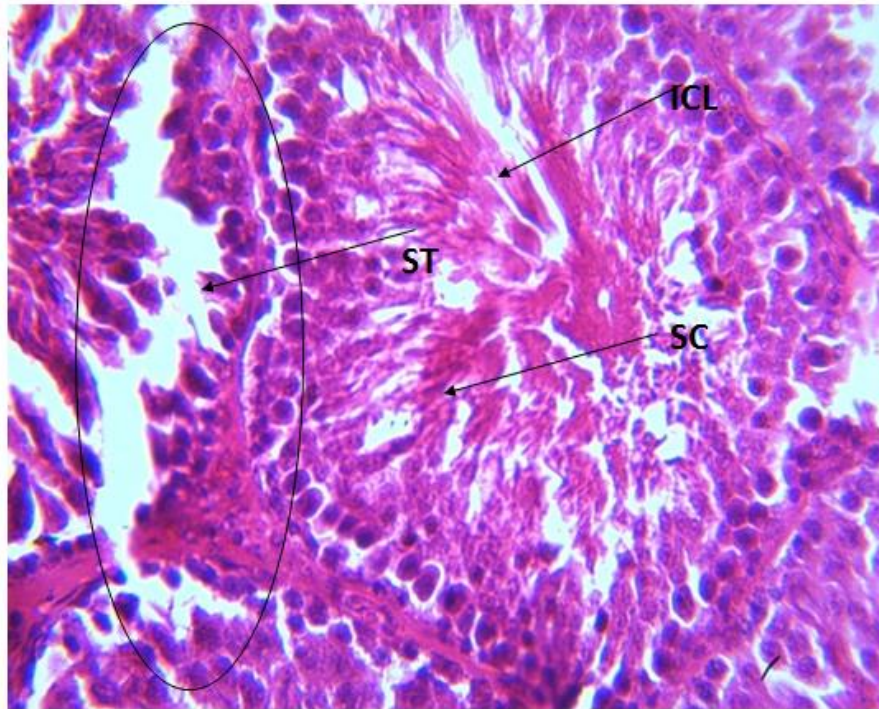


Plate 1: Photomicrograph of testis for control group A. The section of testis (x400)(H/E) shows normal testicular architecture with seminiferous tubule(ST) that are lined with interstitial cells of leydig(ICL),sertoli cell (sc) and well enhanced spermatogenesis (WES).The overall feature appears normal.

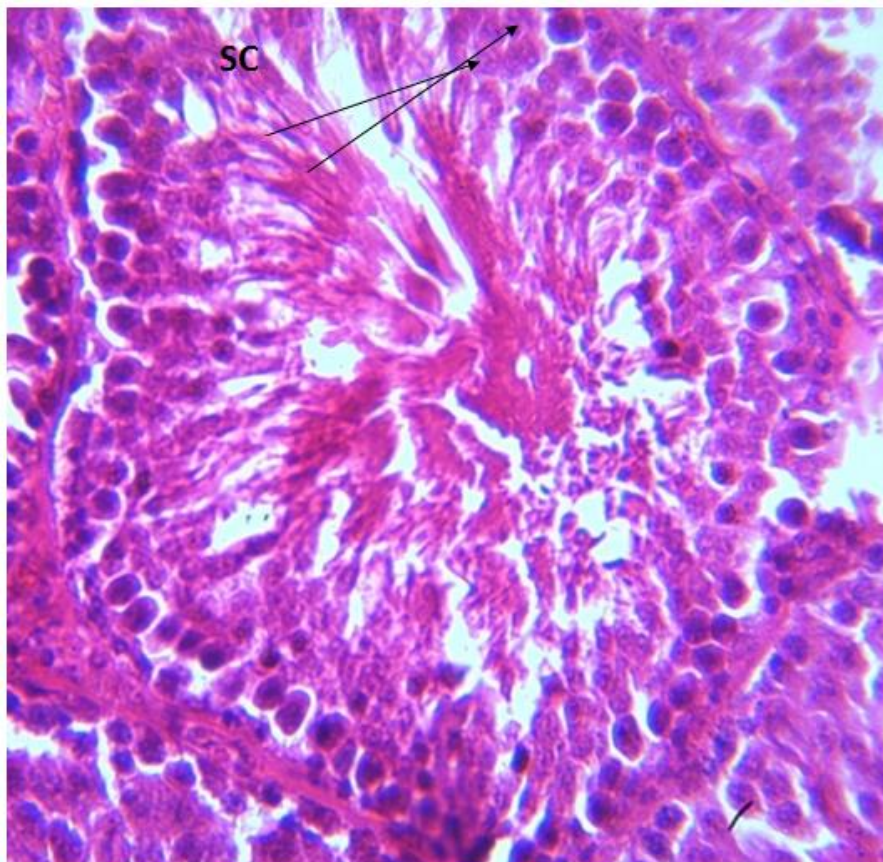


Plate 2: Photomicrograph of testis for group B administered with 200mg/kgBW of *Allium cepa linn* only. The section of testis (x400)(H/E) shows testicular tissue with seminiferous tubule(ST) that are lined with interstitial cells of the leydig(ICL), sertoli cell (sc) and well enhanced spermatogenesis (WES).

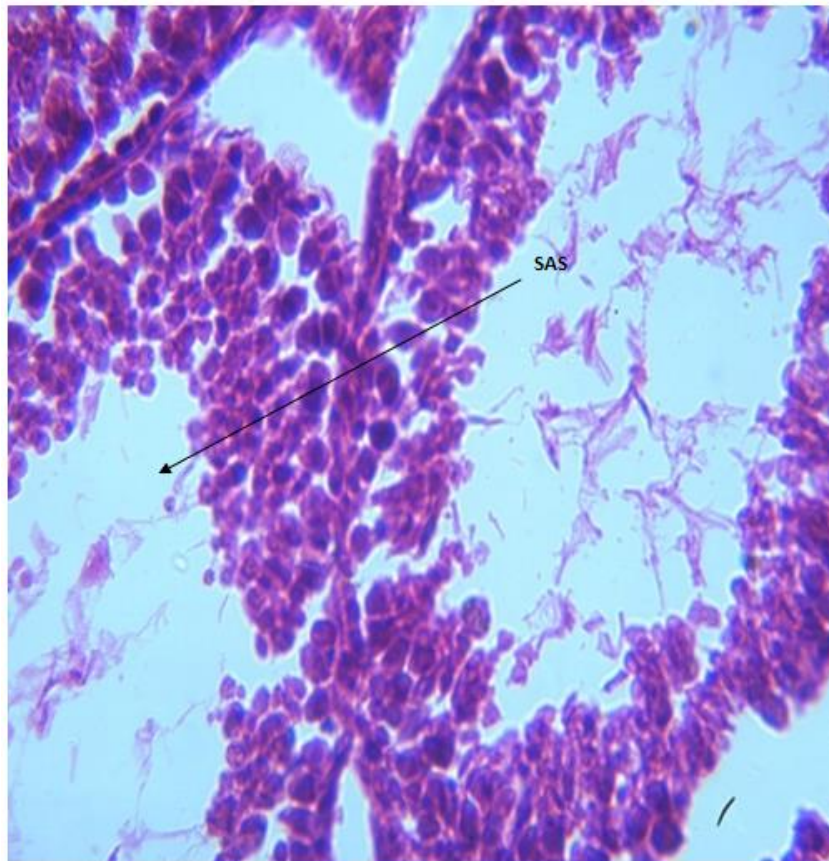


Plate 3: Photomicrograph of testis for group C administered with 90mg/kg BW of $AlCl_3$ only. The section of testis (x400)(H/E) shows severe degeneration with severe arrest of the spermatogenesis (SAS), Severe distortion of the interstitial cell of Leydig (SDICL) and Sertoli cell (SC).

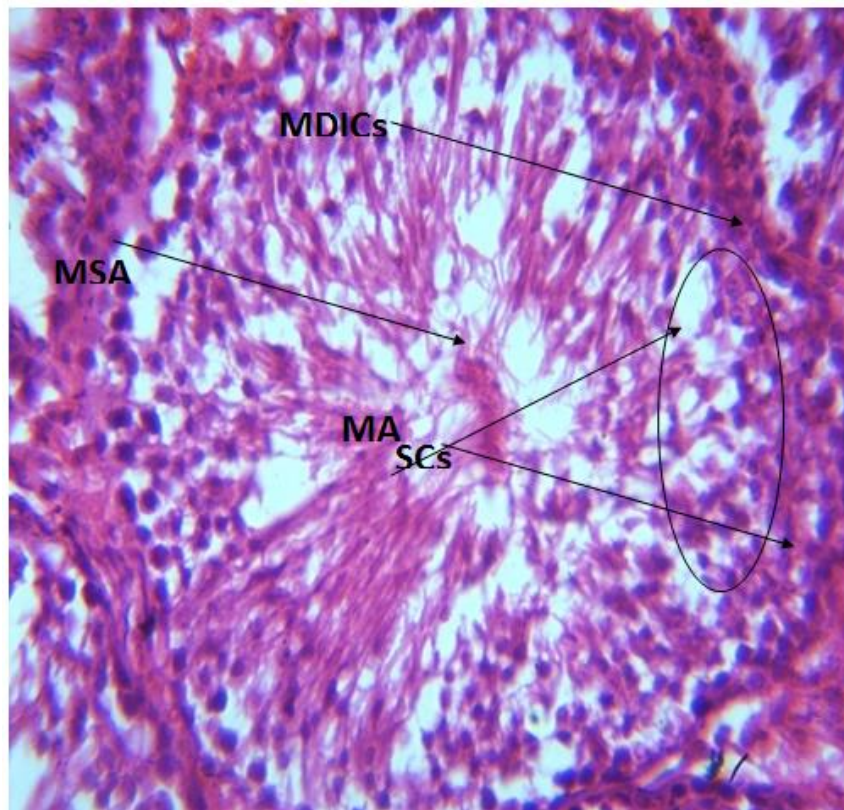


Plate 4: Photomicrograph of testis for group D administered with Aluminum chloride 90mg/kgBW and 200mg/kgBW of *Allium cepa linn* concomitantly. The section of testis (x400)(H/E) shows moderate regeneration with mild distortion (MD) and mild spermatogenic arrest (MSA) and moderate distortion of interstitial cell of Leydig (SDICLs) and Sertoli cell (SCs).

PHOTOMICROGRAPH OF KIDEYS

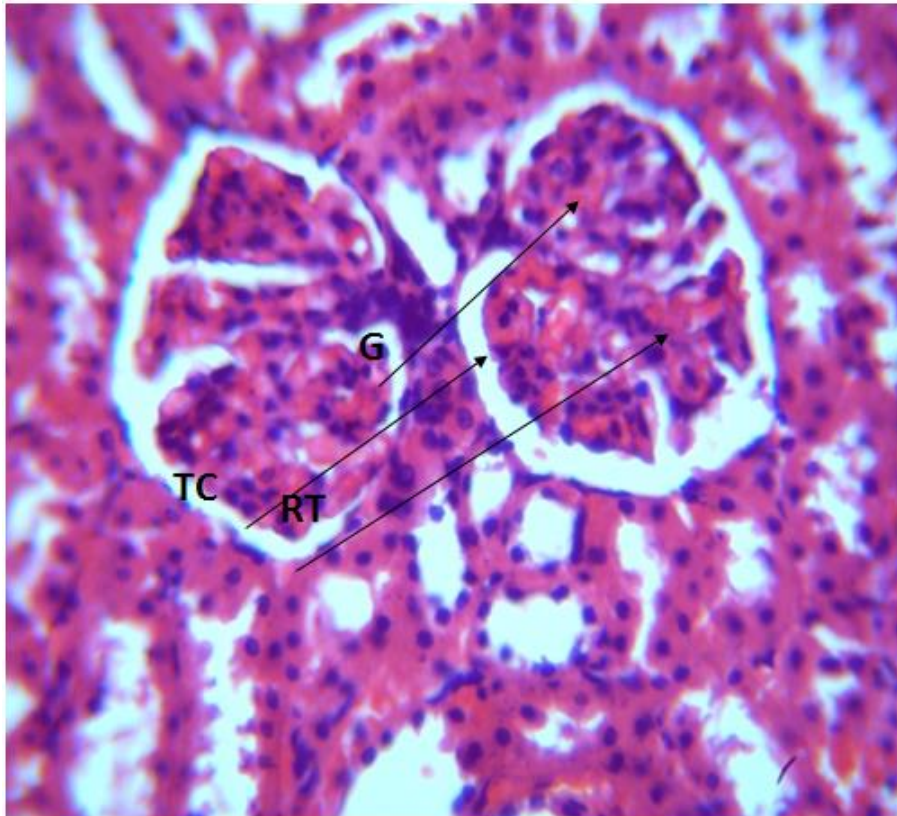


Plate 5: Photomicrograph of kidney for control group. The section of kidney (X400) (H/E) shows normal renal architecture with glomeruli (G), renal tubules (RT) and tubular cell (Tc).

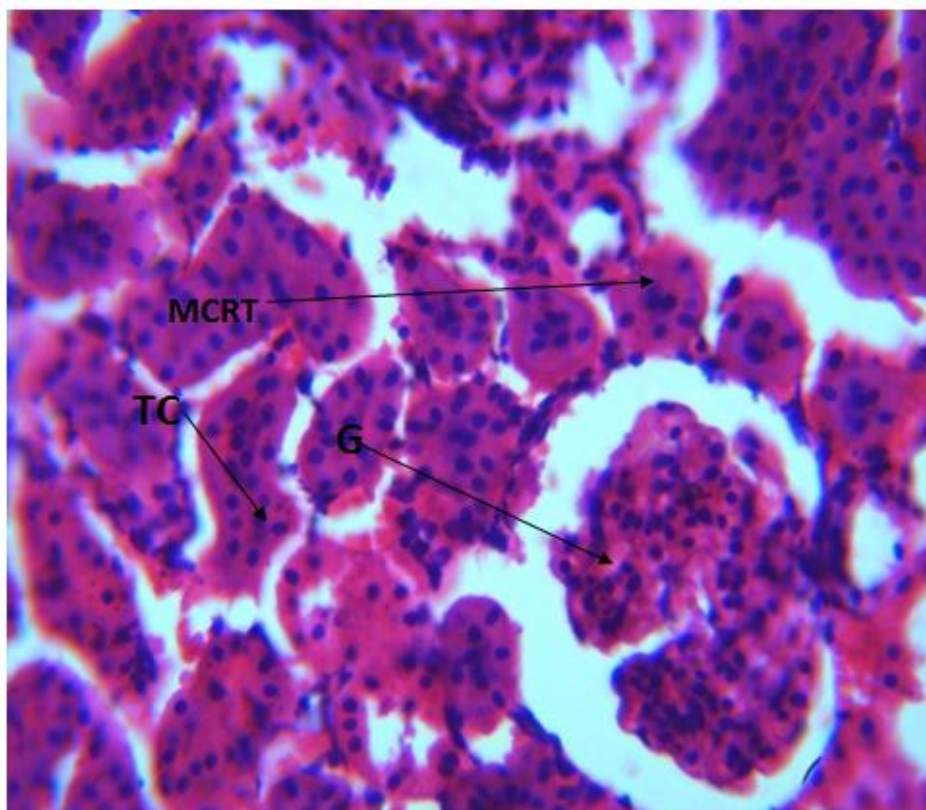


Plate 6: Photomicrograph of kidney for group B (administered with 200mg/kgBW of *Allium cepa* Linn only). The section of kidney (X400)(H/E) shows mild clumping of the renal tubules(MCRT) otherwise normal with glomeruli (G) , renal tubules (RT)and tubular cell (Tc) that appear normal.

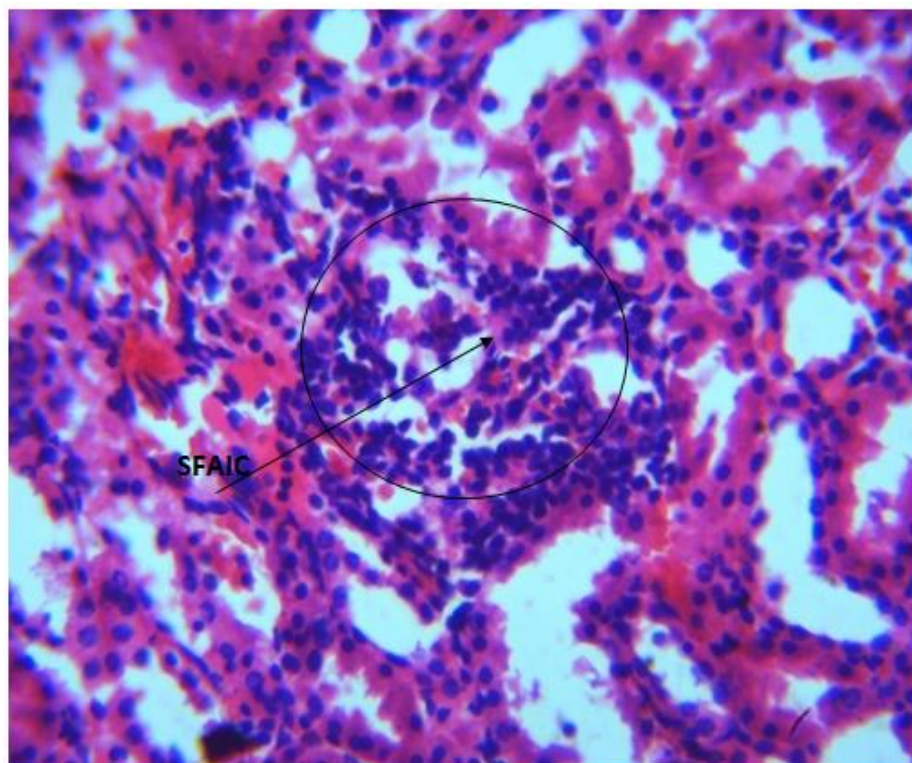


Plate 7: Photomicrograph of kidney for group C administered with 90mg/kgBW of Aluminum chloride ($AlCl_3$) only. The section (x400) (H/E) shows severe renal tissue degeneration with severe focal aggregate of inflammatory cells (SFAIC).

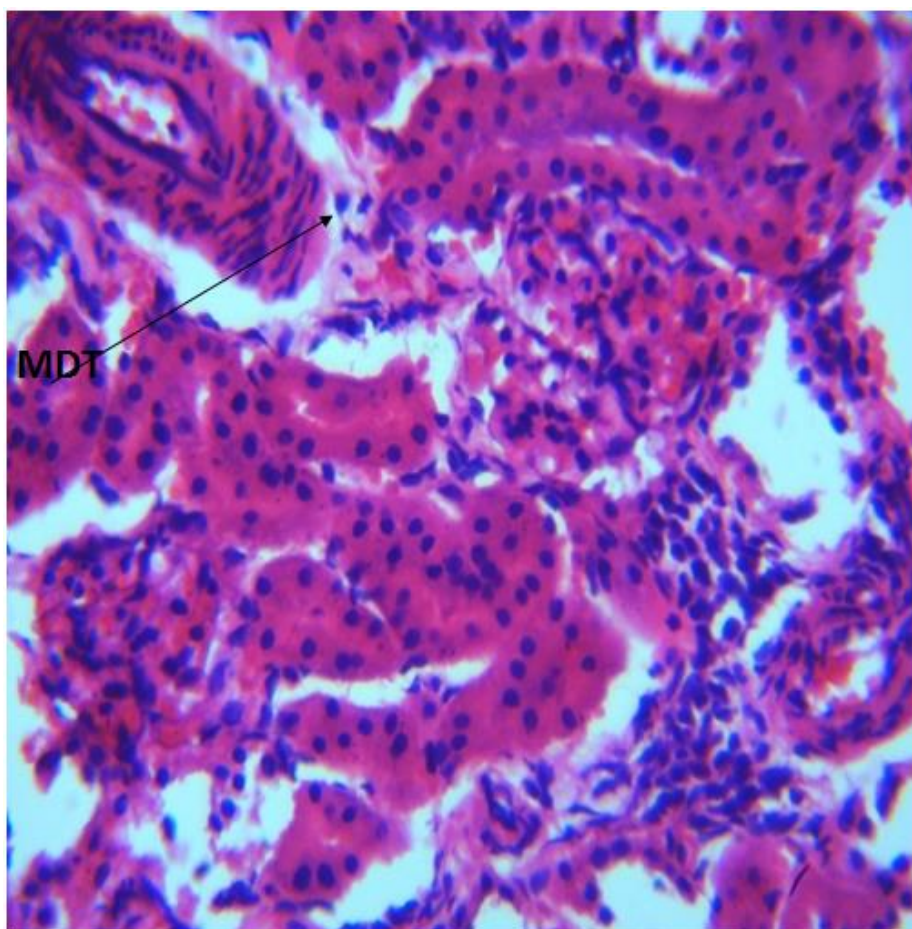


Plate 8: Photomicrograph of kidney for group D administered with 200mg/kg BW of Aluminum chloride & *Allium cepa* linn. The section kidney (x400)(H/E) shows mild regeneration of renal tissue with moderate focal aggregate of inflammation (MAIC) and mild dilation of the tubules (MDT)

Discussion

The impact of metals on reproductive and renal systems has been shown by previous studies (Mestaghanmi et al., 2002; Stella et al., 2005). The present research seeks to determine if AcL extract may prevent or reduce testicular and renal damage caused by AlCl₃ by evaluating several physical, biochemical, and histological parameters associated with reproductive and kidney functioning in intoxicated and treated rats. Weight is defined as the magnitude or quantity of mass or weight. In the field of science and engineering, the weight of an item is often defined as the gravitational force acting on the object (Igal, 2001). A statistically significant increase ($p < 0.05$) in the mean body weight of male Wistar rats was seen in group A. The observed phenomenon may be attributed to physiological factors, since the participants were just exposed to water and standard rats' chows. Experimental group B, which received a dosage of 200 mg/kg per body weight of *Allium cepa* linn juice, exhibited a statistically significant increase in body weight ($p < 0.05$) compared to the control group and the other experimental groups (C and D). The observed phenomenon may be attributed to the abundant antioxidant and biochemical constituents found in *Allium cepa* linn. This finding contradicts the results of a prior investigation conducted by Hosseini et al. (2016), whereby no statistically significant ($p > 0.05$) disparity in the average body weight of rats was seen between the control group and the group treated with 0.5 cm *Allium cepa* over a period of 30 days. The examination of data obtained from group C, which received a dosage of 90 mg/kgBW of aluminum chloride (AlCl₃), demonstrated a statistically significant reduction in the average body weight in comparison to both the control group and the other experimental groups.

Based on this outcome, we noted that AlCl₃ caused a decrease in body weight in the organism. This is likely due to the animals in the group experiencing a decrease in appetite and a fall in their food consumption. The findings of Yousef et al. (2005), Khattab et al. (2010), and Buraimoh et al. (2011) align with the present study, since they observed a statistically significant decrease ($p < 0.05$) in the average body weight of adult Wistar rats after exposure to aluminum chloride. The results of the data analysis conducted on group D, which received a dosage of mg/kg BW of AlCl₃ and 200 mg/kg BW of *Allium cepa* linn juice, indicated a statistically significant rise in average body weight, comparable to the control group. One possible explanation for this phenomenon is that *Allium cepa* linn serves as a food supplement, hence promoting growth. According to the US National Onion Association's study, *Allium cepa* linn extract (AcLE) includes inulin and other antioxidants, including selenium, glutathione, vitamins A, B, and C, as well as flavonoids (US-NOA, 2011; Ige et al., 2017).

The findings derived from the examination of organ weights also revealed statistically significant disparities across the various groups. Group B had a statistically significant ($p < 0.05$) elevation in the relative weights of the testicles and kidneys when compared to the control group. The administration of AlCl₃ at a dosage of 90 mg/kgBW to group C resulted in a substantial reduction ($p < 0.05$) in testicular weight and a significant increase ($*p < 0.05$) in kidney weight. The observed reduction in testicular weight indicates that the application of AlCl₃ resulted in significant histopathological damage. This damage manifested as alterations in the typical structure of the testes, accompanied by severe tissue degeneration and apoptosis of the interstitial cells of Leydig and Sertoli cells.

Notably, there was no evidence of inflammation. Consequently, the tissues underwent shrinkage, leading to a decrease in testicular weight. This assertion is supported by prior research conducted by Yousef et al. (2005) and Khattab et al. (2010), which documented a decrease in both body weight increase and testicular weight after treatment with AlCl₃. The increase in kidney weight might perhaps be attributed to changes in kidney architectures characterized by significant renal tissue regeneration and the presence of a concentrated cluster of inflammatory cells, leading to inflammation. According to Yousef (2014), it has been shown that AlCl₃ has the ability to generate oxidative stress in many organs of rabbits, including the kidney. This finding contradicts the results of prior research conducted by Mussi et al. (1987), McLaughlin et al. (1962), and Steinhagen et al. (1978), which indicated that there was no statistically significant disparity in kidney weights between rats treated with AlCl₃ and the control group. Group D was administered a dosage of 90 mg/kg of AlCl₃ and 200 mg/kg of AcL. The effects of these treatments were shown to be statistically significant, comparable to those seen in group A. The suppressed or averted inflammation in the group might be attributed to the anti-oxidant and anti-inflammatory activities of *Allium cepa* linn extract. This finding aligns with the previous research conducted by Griffiths et al. (2002), which documented the beneficial properties of *Allium cepa* linn (commonly known as red onions) in therapeutic contexts. These properties include strong anti-inflammatory, anti-carcinogenic, hypolipidemic, anti-thrombotic, anti-asthmatic, anti-bacterial, and antifungal antioxidant effects.

The current research observed a statistically significant increase ($*P < 0.05$) in sperm motility, total sperm count, and normal sperm morphology data analysis in groups B (given with 200 mg/kgBW of AcL juice alone) and C (provided with 90 mg/kgBW of AlCl₃ only), respectively. The observed decline in sperm parameters within Group C may be attributed to the induction of oxidative stress by AlCl₃, resulting in a subsequent decrease in sperm quality. Consistent with previous research conducted by Hovatta et al. (1998), Singh et al. (1998), and Yousef et al. (2007), it has been shown that rats treated with AlCl₃ exhibit reduced sperm motility, count, and viability. The observed decline in sperm count in rats given with AlCl₃ may be attributed to a drop in gonadotropins and testosterone levels, since these hormones play a crucial role in the process of spermatogenesis. Luteinizing hormone (LH) induces the secretion of testosterone from the interstitial cells of Leydig. This testosterone, in conjunction with interstitial cell stimulating hormones (ICSH), also known as follicle-stimulating hormone (FSH) in females, plays a crucial role in the stimulation of spermatogenesis (Sembuligam, 2004).

The decrease in these hormones in rats treated with AlCl₃ resulted in a reduced sperm count. The observed decrease in motility and viability, along with the presence of heightened morphological abnormalities, in rats treated with AlCl₃ may be linked to an elevation in nitric oxide levels induced by AlCl₃. Previous studies have indicated that this elevation leads to a decrease in the rate and motility of sperm cells, as well as an increase in morphological abnormalities (Latchoumycandane et al., 2002). The data analysis of sperm motility revealed a substantial increase ($p < 0.05$) in both total sperm count and normal sperm morphology in group D that received simultaneous administration of AlCl₃ and AcL extract. The presence of biochemical ingredients (US-NOA, 2011, Ige et al., 2017) and flavonoid is likely responsible for this phenomenon,

as seen in the phytochemical study of *Allium cepa* linn (Oyewusi et al., 2015). Onion (*Allium cepa*) is a very abundant source of flavonoids in the human diet (Lachman et al., 2003). Flavonoids have potent antioxidant properties as a result of their capacity to effectively eliminate free radicals originating from fatty acids and oxygen. This finding aligns with prior research conducted by Griffiths et al. (2002), Rajeev and Narmada (2006), and Yang et al. (2006), which indicated that the abundant chemical and antioxidant characteristics of *Allium cepa* have the potential to safeguard DNA and other crucial molecules against oxidative harm. Consequently, these properties may enhance sperm health parameters, leading to an increase in male fertility rates. The study of abnormal sperm morphology and Pus cells data revealed a statistically significant ($p < 0.05$) decrease in groups B and D, whereas a statistically significant increase was detected in group C compared to the control group. The observed increase in group C, which was supplied with a dosage of 0.2 ml of $AlCl_3$, is likely attributed to a decrease in sperm motility and viability, as previously mentioned. This is corroborated by the prior investigation conducted by Latchoumycandane et al. in 2002.

The analysis of data in ICSH and Testosterone showed a notable reduction in group C when given a dosage of 90 mg/kgBW of $AlCl_3$. However, there was no significant difference ($p > 0.05$) seen in groups B (treated with a dosage of 200 mg/kgBW of AcL extract) and D (treated with both $AlCl_3$ and AcL extracts at the same time). The significant decrease in serum testosterone and ICSH levels in group C may indicate a disruption in the functionality of the Leydig cells. The results of our study are supported by the findings of Yakubu et al. (2017), who also observed a substantial decrease in blood levels of LH, FSH, and testosterone in adult rats after oral administration of aluminum chloride. According to Guo et al. (2005), it has been proposed that aluminum intoxication might lead to the generation of nitric oxide (NO), which has the potential to inhibit the synthesis of testosterone. In a similar vein, Dobashi et al. (2001) also noted that the suppressive impact of nitric oxide (NO) on Leydig cells has the potential to impede the production of testosterone. The potential reduction in testosterone synthesis after aluminum exposure might be attributed to the reduced activity of the 17-ketosteroid reductase enzyme, which is responsible for converting androstenedione into testosterone (Busselberg et al., 1994; Mills et al., 1994; Yousef et al., 2005). This finding suggests a potential connection between the reduction in FSH and LH levels and the inhibitory effect of aluminum on calcium channels. This inhibition hinders the production of gonadotrophins from the hypothalamus, since the hypothalamus relies on calcium ions for the release of gonadotrophin-releasing hormone (GnRH).

The examination of urea and creatinine data revealed that $AlCl_3$ caused a substantial increase in urea and creatinine levels. There was no statistically significant difference seen in the blood levels of urea and creatinine concentration between the test group (group B) treated just with *Allium cepa* linn extract and group D treated with both $AlCl_3$ and *Allium cepa* linn extract simultaneously, as compared to the control group. The observed elevation in urea and creatinine levels within the group treated with $AlCl_3$ may be attributed to the oxidative stress induced by $AlCl_3$, resulting in compromised renal function. This finding aligns with the prior research conducted by Ige and Aiyeola (2017), which demonstrated a significant elevation in serum urea and creatinine levels in rats exposed to aluminum. The combination of *Allium*

cepa and $AlCl_3$ poses an overwhelming challenge for human beings (Krewski et al., 2007). The concurrent administration of *Allium cepa* to rats exposed to aluminum effectively reduces the notable elevation in blood urea and creatinine levels. This finding aligns with a prior investigation conducted by Ige and Aiyeola (2017), which documented a reduction in higher levels of urea and creatinine concentration.

Histopathological analysis of animal tissues plays a crucial role in evaluating the reproductive and renal hazards associated with these conditions. When evaluating the toxicity of male reproduction, it is recommended to utilize the testis as the most sensitive endpoint. (Turner et al., 2007). The control group's photomicrograph exhibited typical testicular structures characterized by interstitial cells composed of Leydig and Sertoli cells. The general characteristics are accurately depicted. Group B, treated with *Allium cepa* Linn, had intact architectural testicular tissues that were bordered with interstitial cells of Leydig and Sertoli cells. Additionally, there was a notable improvement in spermatogenesis. The potential beneficial outcomes reported might perhaps be attributed to the abundant biochemical and antioxidant characteristics of *Allium cepa* linn extract, as shown by previous studies (Lachman et al., 2003; US-NOA, 2011; Ige et al., 2017).

The histopathological analysis of the testis showed significant changes in group C treated with $AlCl_3$. The observed changes include the degradation of spermatogenic cells, reduction in size of seminiferous tubules, thinning of the germinal epithelium, exfoliation of germ cells, depletion of spermatozoa from the lumina, significant deformation and shedding in the germinal epithelium, and degeneration of Leydig cells. This finding aligns with prior research conducted by Khattab et al. (2010), Nuhair (2015), and Yakubu et al. (2017), which documented comparable histological alterations in rats and mice exposed to aluminum. According to Mayas et al. (2005),

Oxidative stress may lead to histological alterations in testicular tissue by causing cellular harm and hindering the steroidogenic activity of Leydig cells. Investigations conducted on animal subjects subjected to arsenic treatment have shown a comparable correlation between testicular damage and oxidative stress induced by free radicals. The studies conducted by Morakinyo et al. (2010), Predes et al. (2011), Dorostghoal et al. (2013), Kalender et al. (2013), and Pandey and Jain (2015) have examined the effects of cadmium, lead, mercury, and molybdenum. According to the findings of Ige and Akhigbe (2012), the infiltration of aluminum across the blood-testis barrier has the potential to induce modifications in spermatogenic cells. Aluminum's direct impact on Sertoli cells has the potential to disrupt intercellular bridges, resulting in the exfoliation of germ cells. According to the findings of Kim et al. (2001), the inhibition of a cell adhesion protein, namely cadherin, in Sertoli cells resulted in an augmented shedding of seminiferous epithelial cells, ultimately resulting in tubular atrophy. The effects found on germ cells are likely attributed to heightened levels of oxidative stress and lipid peroxidation, resulting in significant death of germ cells. Previous studies have shown comparable instances of apoptosis and necrosis in germ cells inside the testis of animals subjected to aluminum treatment (Yousef et al., 2009; Khattab et al., 2010). The photomicrograph of group D, which was treated simultaneously with $AlCl_3$ and *Allium cepa* linn extract, exhibited a moderate level of germ cell regeneration, a moderate degree of distortion in the interstitial cells

of leydig and sertoli cells, and a modest level of distortion and spermatogenic arrest.

The histopathological analysis of the kidney showed changes in the structure of the kidney in group C treated with AlCl₃. This included significant regeneration of renal tissue, accompanied by a concentrated cluster of inflammatory cells. This may be attributed to the harmful impact caused by the oral administration of AlCl₃. This finding contradicts the results of the prior research. Steinhagen et al. (1978) reported that the kidneys of group B exhibited little glomerulus-induced aggregation of the renal tubules, but the tubular cells seemed to be within normal parameters. The kidneys of Hartley guinea pigs exposed to AlCl₃ did not exhibit any histopathological changes. Group D exhibited a minor degree of renal regeneration accompanied by a considerable concentration of inflammation in a specific area. The possible antioxidant and anti-inflammatory properties of *Allium cepa* linn extract have been suggested by Griffith et al. (2002).

CONCLUSION

Based on the findings, it was observed that AlCl₃ had adverse effects on testicular and renal parameters in adult Wistar rats. The medicinal qualities of onion juice mitigated these effects. Therefore, the findings of this investigation indicate that the administration of AcL (Red Onion Juice) extract has protective properties against testicular and renal damage generated by AlCl₃.

RECOMMENDATION

So I can say that to eliminate the potential hazards of AlCl₃ on male reproductive and renal function, it is better to consume this vegetable plant, '*Allium cepa* Linn', that is rich in natural antioxidant potential. I also recommend that further research be carried out on the effect of this compound (AlCl₃) on other vital organs like the lung, pancreas, spleen, etc.

REFERENCES

1. Malekshah, A. K., Torabizadeh, Z., & Naghshwar, F. (2005). Developmental toxicity of aluminum from high doses of AlCl₃ in mice. *JOURNAL OF APPLIED RESEARCH IN CLINICAL AND EXPERIMENTAL THERAPEUTICS*, 5(4), 575.
2. Abdel-Maksoud, G., & El-Amin, A. R. (2011). A REVIEW ON THE MATERIALS USED DURING THE MUMMIFICATION PROCESSES IN ANCIENT EGYPT. *Mediterranean Archaeology & Archaeometry*, 11(2).
3. Agency for toxic substances and disease registry (ATSDR). (2008). Toxicological profile for aluminum, US Department of Health and Human Services.
4. Agricultural Research Service (ARS) & United States Department of Agriculture. (USDA) (2017).
5. Alessio, L., Apostoli, P., Ferioli, A., Di Sipio, I., Mussi, I., Rigosa, C., & Albertini, A. (1989). Behaviour of biological indicators of internal dose and some neuro-endocrine tests in aluminium workers. *La Medicina del Lavoro*, 80(4), 290-300.
6. Alfrey, A. C., LeGendre, G. R., & Kaehny, W. D. (1976). The dialysis encephalopathy syndrome: possible aluminum intoxication. *New England Journal of Medicine*, 294(4), 184-188.
7. Alvarez, J. G., & Storey, B. T. (1984). Assessment of cell damage caused by spontaneous lipid peroxidation in rabbit spermatozoa. *Biology of reproduction*, 30(2), 323-331.
8. Alvarez, J. G., & Storey, B. T. (1984). Assessment of cell damage caused by spontaneous lipid peroxidation in rabbit spermatozoa. *Biology of reproduction*, 30(2), 323-331.
9. Anane, R., & Creppy, E. E. (2001). Lipid peroxidation as pathway of aluminium cytotoxicity in human skin fibroblast cultures: prevention by superoxide dismutase+ catalase and vitamins E and C. *Human & experimental toxicology*, 20(9), 477-481.
10. Andress, K. T., & Carpenter, C. (1934). Kristallhydrate: II. Die Struktur von Chromchlorid-und Aluminiumchloridhexahydrat. *Zeitschrift für Kristallographie-Crystalline Materials*, 87(1-6), 446-463.
11. McCabe, A., O'Donnell, M., & Whittaker, R. (Eds.). (2009). *Advances in language and education*. Bloomsbury Publishing.
12. Ansari, N. A. (2007). Onion cultivation and production in Iran. *Middle East. Russ. J. Plant Sci. Biotechnol*, 1(2), 26-38.
13. Kalaiselvi, A., Suganthi, O. M., Govindassamy, P., Vasantharaja, D., Gowri, B., & Ramalingam, V. (2014). Influence of aluminium chloride on antioxidant system in the testis and epididymis of rats. *Iranian journal of Toxicology*, 8(24), 991-997.
14. Balercia, G., Moretti, S., Vignini, A., Magagnini, M., Mantero, F., Boscaro, M., ... & Mazzanti, L. (2004). Role of nitric oxide concentrations on human sperm motility. *Journal of Andrology*, 25(2), 245-249.
15. Banks, W. A., & Kastin, A. J. (1989). Aluminum-induced neurotoxicity: alterations in membrane function at the blood-brain barrier. *Neuroscience & Biobehavioral Reviews*, 13(1), 47-53.
16. Bilkei-Gorzó, A. (1993). Neurotoxic effect of enteral aluminium. *Food and chemical toxicology*, 31(5), 357-361.
17. Block, E. (2010). *Allium botany and cultivation, ancient and modern. Garlic and other alliums: the lore and the science*, 1-32.
18. Buraimoh, A. A., Ojo, S. A., Hambolu, J. O., & Adebisi, S. S. (2011). Behavioural endpoints of adult wistar rats, following aluminium chloride exposure. *Br J Pharmacol Toxicol*, 2(5), 273-276.
19. Busselberg, D., Platt, B., Michael, D., Carpenter, D. O., & Haas, H. L. (1994). Mammalian voltage-activated calcium

- channel currents are blocked by Pb²⁺, Zn²⁺, and Al³⁺. *Journal of Neurophysiology*, 71(4), 1491-1497.
20. Büsselberg, D. (1995). Calcium channels as target sites of heavy metals. *Toxicology letters*, 82, 255-261.
21. Carreau, S., Bourguiba, S., Lambard, S., Galeraud-Denis, I., Genissel, C., & Levallet, J. (2002). Reproductive system: aromatase and estrogens. *Molecular and cellular endocrinology*, 193(1-2), 137-143.
22. Chaurasia, B. (2016). *Human anatomy regional and applied dissection and clinical*. CBS Publishers & Distributors Pvt Ltd.
23. Cheng, C. Y., & Mruk, D. D. (2012). The blood-testis barrier and its implications for male contraception. *Pharmacological reviews*, 64(1), 16-64.
24. Clapp, W. L. (2009). Renal anatomy. *Silva's Diagnostic Renal Pathology*; Zhou, XJ, Laszik, Z., Nadasdy.
25. Cope, R. B. (2005). Allium species poisoning in dogs and cats. *VETERINARY MEDICINE-BONNER SPRINGS THEN EDWARDSVILLE-*, 100(8), 562.
26. Robbins, S. L., Cotran, R. S., Kumar, V., Abbas, A. K., Fausto, N., & Aster, J. C. (2010). Robbins and Cotran pathologic basis of disease. In *Robbins and Cotran pathologic basis of disease* (pp. 1450-1450).
27. Dai, X., Ding, Y., Zhang, Z., Cai, X., & Li, Y. (2013). Quercetin and quercitrin protect against cytokine-induced injuries in RINm5F β -cells via the mitochondrial pathway and NF- κ B signaling. *International journal of molecular medicine*, 31(1), 265-271.
28. Danovich Tove. (2018). Stop Crying! Tear-Free Onions Are Here . National Public Radio. Retrieved April 13, 2018.
29. Dobashi, M., Fujisawa, M., Yamazaki, T., Okuda, Y., Kanzaki, M., Tatsumi, N., ... & Kamidono, S. (2001). Inhibition of steroidogenesis in Leydig cells by exogenous nitric oxide occurs independently of steroidogenic acute regulatory protein (star) mRNA. *Archives of andrology*, 47(3), 203-209.
30. Domingo, J. L., Paternain, J. L., Llobet, J. M., & Corbella, J. (1987). The effects of aluminium ingestion on reproduction and postnatal survival in rats. *Life sciences*, 41(9), 1127-1131.
31. Dorostghoal, M., Seyyednejad, S. M., & Jabari, A. (2014). Protective effects of *Fumaria parviflora* L. on lead-induced testicular toxicity in male rats. *Andrologia*, 46(4), 437-446.
32. Dua, R., & Gill, K. D. (2001). Aluminium phosphide exposure: implications on rat brain lipid peroxidation and antioxidant defence system. *Pharmacology & toxicology*, 89(6), 315-319.
33. Ekaluo, U. B., Uno, U. U., Edu, N. E., Ekpo, P. B., Etta, S. E., & Volunteer, B. O. (2016). Protective role of onion (*Allium cepa* L.) on caffeine induces spermatotoxicity in albino rats. *J. Appl. Life Sci. Int*, 4, 1-7.
34. Emamian, S. A., Nielsen, M. B., Pedersen, J. F., & Ytte, L. (1993). Kidney dimensions at sonography: correlation with age, sex, and habitus in 665 adult volunteers. *AJR. American journal of roentgenology*, 160(1), 83-86.
35. Block, E. (2010). Allium botany and cultivation, ancient and modern. *Garlic and other alliums: the lore and the science*, 1-32.
36. European food safety authority (EFSA). (2008). Safety of aluminum from dietary intake. *Journal of EFSA*; 3(1):754, 1-34.
37. Flora, S. J. S., Mittal, M., & Mehta, A. (2008). Heavy metal induced oxidative stress & its possible reversal by chelation therapy. *Indian Journal of Medical Research*, 128(4), 501-523.
38. Flora, S. J., Mehta, A., Satsangi, K., Kannan, G. M., & Gupta, M. (2003). Aluminum-induced oxidative stress in rat brain: response to combined administration of citric acid and HEDTA. *Comparative Biochemistry and Physiology Part C: Toxicology & Pharmacology*, 134(3), 319-328.
39. Fritsch, R. M., & Friesen, N. (2002). Evolution, domestication and taxonomy. *Allium crop science: recent advances*, 5-30.
40. Reich, H. J., & Rigby, J. H. (Eds.). (1999). *Handbook of Reagents for Organic Synthesis, Acidic and Basic Reagents*. Wiley-Blackwell.
41. Gil-Guzman, E., Ollero, M., Lopez, M. C., Sharma, R. K., Alvarez, J. G., Thomas Jr, A. J., & Agarwal, A. (2001). Differential production of reactive oxygen species by subsets of human spermatozoa at different stages of maturation. *Human Reproduction*, 16(9), 1922-1930.
42. Glodny, B., Unterholzner, V., Taferner, B., Hofmann, K. J., Rehder, P., Strasak, A., & Petersen, J. (2009). Normal kidney size and its influencing factors-a 64-slice MDCT study of 1.040 asymptomatic patients. *BMC urology*, 9, 1-13.
43. Gonzalez, M. A., Alvarez, M. D. L., Pisani, G. B., Bernal, C. A., Roma, M. G., & Carrillo, M. C. (2007). Involvement of oxidative stress in the impairment in biliary secretory function induced by intraperitoneal administration of aluminum to rats. *Biological trace element research*, 116, 329-348.
44. Greeley C.O. (2011). History of onions. US National Onion Association
45. Greenwood, N. N., & Earnshaw, A. (2012). *Chemistry of the Elements*. Elsevier.

46. Griffiths, G., Trueman, L., Crowther, T., Thomas, B., & Smith, B. (2002). Onions—a global benefit to health. *Phytotherapy Research: An International Journal Devoted to Pharmacological and Toxicological Evaluation of Natural Product Derivatives*, 16(7), 603-615.
47. Guercio, V., Galeone, C., Turati, F., & La Vecchia, C. (2014). Gastric cancer and allium vegetable intake: a critical review of the experimental and epidemiologic evidence. *Nutrition and cancer*, 66(5), 757-773.
48. Guo, C. H., Lin, C. Y., Yeh, M. S., & Hsu, G. S. W. (2005). Aluminum-induced suppression of testosterone through nitric oxide production in male mice. *Environmental toxicology and pharmacology*, 19(1), 33-40.
49. Gutteridge, J. M., Quinlan, G. J., Clark, I., & Halliwell, B. (1985). Aluminium salts accelerate peroxidation of membrane lipids stimulated by iron salts. *Biochimica et Biophysica Acta (BBA)-Lipids and Lipid Metabolism*, 835(3), 441-447.
50. Hala, A. H., Khattab, Z. A., Abdallah, G., & Kamel, M. (2010). Grape seed extract alleviate reproductive toxicity caused by aluminium chloride in male rats. *J Am Sci*, 6(12), 352-361.
51. Haynes, W. M. (2016). *CRC handbook of chemistry and physics*. CRC press.
52. Otto, H., Keith, H. L., Chanakya, M., Karl, W., Wolfgang, H., Hans, S., ... & Norbert, R. (2007). Aluminum Compounds//Inorganic in Ullmann's Encyclopedia of Industrial Chemistry.
53. Hosseini Ahar, N., & Safi, S. H. (2016). Effect of Allium sepa seed extract on body and testicular weight, mature gametes and parietal cells of male rats. *BIOSCIENCE BIOTECHNOLOGY RESEARCH COMMUNICATIONS*, 9(4), 828-832.
54. Al Dera, H. S. (2016). Protective effect of resveratrol against aluminum chloride induced nephrotoxicity in rats. *Saudi medical journal*, 37(4), 369.
55. Inderbir, S. (2006). Textbook of human histology with color atlas. *New Delhi: Jaypee Brithers Medical Publishers*.
56. Ige, S. F., & Akhigbe, R. E. (2012). The role of Allium cepa on aluminum-induced reproductive dysfunction in experimental male rat models. *Journal of human reproductive sciences*, 5(2), 200-205.
57. Ige, S. F., Olaleye, S. B., Akhigbe, R. E., Akanbi, T. A., Oyekunle, O. A., & Udoh, U. A. S. (2012). Testicular toxicity and sperm quality following cadmium exposure in rats: Ameliorative potentials of: Allium cepa. *Journal of Human Reproductive Sciences*, 5(1), 37-42.
58. Ige, S. F., Akhigbe, R. E., Adewale, A. A., Badmus, J. A., Olaleye, S. B., Ajao, F. O., ... & Owolabi, O. Q. (2011). Effect of Allium cepa (Onion) Extract on cadmium induced nephrotoxicity in rats. *Kidney Res J*, 1(1), 41-47.
59. Ige, S. F., & Aiyeola, A. (2017). Effect of aqueous Allium cepa extract from red onion on aluminum chloride-induced anemia in female rats. *Journal of Applied Sciences and Environmental Management*, 21(7), 1286-1290.
60. Ige, S. F., Adeniyi, M. J., & Iyalla, G. O. (2017). Allium cepa mitigates aluminum chloride-induced hepatotoxicity in male wistar rats. *J Biomedical Sci*, 6(4), 27.
61. Rocchi, J. A., & Stewart, T. J. (2016). *U.S. Patent No. 9,482,496*. Washington, DC: U.S. Patent and Trademark Office.
62. Joanna Klein. (2017). Why Onions Make You Cry. *The New York Times*. Retrieved 16 April 2018.
63. Jomova, K., & Valko, M. (2011). Advances in metal-induced oxidative stress and human disease. *Toxicology*, 283(2-3), 65-87.
64. Kalender, S., Uzun, F. G., Demir, F., Uzunhisarcikli, M., & Aslanturk, A. (2013). Mercuric chloride-induced testicular toxicity in rats and the protective role of sodium selenite and vitamin E. *Food and chemical toxicology*, 55, 456-462.
65. Keith L.M, Arthur F.D, and Anne, M.A. (2014). *Clinical Oriented Anatomy*. 7th Edtion. Lippincott Williams and Wilkins.
66. Moore, K. L., Persaud, T. V. N., Torchia, M. G., & Persaud, T. (2008). *The developing human: clinically oriented embryology*. Saunders.
67. Khaki, A., Khaki, A. A., & Rajabzadeh, A. (2017). The effects of Permethrin and antioxidant properties of Allium cepa (onion) on testicles parameters of male rats. *Toxin reviews*, 36(1), 1-6.
68. Hala, A. H., Khattab, Z. A., Abdallah, G., & Kamel, M. (2010). Grape seed extract alleviate reproductive toxicity caused by aluminium chloride in male rats. *J Am Sci*, 6(12), 352-361.
69. Khattab, F. K. I., & Khattab, I. (2007). Histological and ultrastructural studies on the testis of rat after treatment with aluminium chloride. *Aust J Basic Appl Sci*, 1(1), 63-72.
70. Khattab, F. K. I., & Khattab, I. (2007). Histological and ultrastructural studies on the testis of rat after treatment with aluminium chloride. *Aust J Basic Appl Sci*, 1(1), 63-72.
71. Kim, J. M., Ghosh, S. R., Weil, A. C., & Zirkin, B. R. (2001). Caspase-3 and caspase-activated deoxyribonuclease are associated with testicular germ cell apoptosis resulting from

- reduced intratesticular testosterone. *Endocrinology*, 142(9), 3809-3816.
72. Kleijnen, J., Knipschild, P., & Ter Riet, G. (1989). Garlic, onions and cardiovascular risk factors. A review of the evidence from human experiments with emphasis on commercially available preparations [see comments]. *British Journal of Clinical Pharmacology*, 28(5), 535-544.
73. Klöppel, H., Fliedner, A., & Kördel, W. (1997). Behaviour and ecotoxicology of aluminium in soil and water-Review of the scientific literature. *Chemosphere*, 35(1-2), 353-363.
74. Krewski, D., Yokel, R. A., Nieboer, E., Borchelt, D., Cohen, J., Harry, J., ... & Rondeau, V. (2007). Human health risk assessment for aluminium, aluminium oxide, and aluminium hydroxide. *Journal of Toxicology and Environmental Health, Part B*, 10(S1), 1-269.
75. Krishnamoorthy, G., Murugesan, P., Muthuvel, R., Gunadharini, D. N., Vijayababu, M. R., Arunkumar, A., ... & Arunakaran, J. (2005). Effect of Aroclor 1254 on Sertoli cellular antioxidant system, androgen binding protein and lactate in adult rat in vitro. *Toxicology*, 212(2-3), 195-205.
76. Kumar, A., Bora, K. S., Jaggi, A. S., & Shri, R. (2016). Comparative evaluation of neuroprotective effect of three varieties of *Allium cepa* in chronic constriction injury induced neuropathic pain. *The Thai Journal of Pharmaceutical Sciences*, 40(1), 9-20.
77. Kutlubay, R., Oğuz, E. O., Can, B., Güven, M. C., Sinik, Z., & Tuncay, Ö. L. (2007). Vitamin E protection from testicular damage caused by intraperitoneal aluminium. *International Journal of Toxicology*, 26(4), 297-306.
78. Mohamed, G. A. (2013). Alliucide A: a new antioxidant flavonoid from *Allium cepa* L. *Phytopharmacology*, 4(2), 220-227.
79. Latchoumycandane, C., Chitra, K. C., & Mathur, P. P. (2002). The effect of methoxychlor on the epididymal antioxidant system of adult rats. *Reproductive Toxicology*, 16(2), 161-172.
80. Lee, E. J., Rezenom, Y. H., Russell, D. H., Patil, B. S., & Yoo, K. S. (2012). Elucidation of chemical structures of pink-red pigments responsible for 'pinkening' in macerated onion (*Allium cepa* L.) using HPLC-DAD and tandem mass spectrometry. *Food chemistry*, 131(3), 852-861.
81. Llobet, J. M., Colomina, M. T., Sirvent, J. J., Domingo, J. L., & Corbella, J. (1995). Reproductive toxicology of aluminum in male mice. *Fundamental and applied toxicology*, 25(1), 45-51.
82. Lorke, D. (1983). A new approach to practical acute toxicity testing. *Archives of toxicology*, 54, 275-287.
83. LUKES, T. (1986). Factors governing the greening of garlic puree. *Journal of Food Science*, 51(6), 1577-1577.
84. Golub, M. S., & Germann, S. L. (2001). Long-term consequences of developmental exposure to aluminum in a suboptimal diet for growth and behavior of Swiss Webster mice. *Neurotoxicology and teratology*, 23(4), 365-372.
85. Mayyas, I., Elbetieha, A., Khamas, W., & Khamas, W. A. (2005). Evaluation of reproductive and fertility toxic potentials of aluminum chloride on adult male mice. *Journal of animal and veterinary advances*.
86. Mescher, A. L. (2009). *Junqueira's Basic Histology: Text & Atlas*. Ed12.
87. Mestaghanimi, H., El Amrani, S., Dauca, M., & Saile, R. (2002). Effects of aluminium chloride on some essential elements in pregnant rats and their offspring. *Revue Marocaine des Sciences Agronomiques et Vétérinaires*, 22(4), 227-234.
88. Mills, L. R., Niesen, C. E., So, A. P., Carlen, P. L., Spigelman, I., & Jones, O. T. (1994). N-type Ca²⁺ channels are located on somata, dendrites, and a subpopulation of dendritic spines on live hippocampal pyramidal neurons. *Journal of Neuroscience*, 14(11), 6815-6824.
89. Moore, K. L., Arthur, F. D., & Anne, M. R. A. (2014). *Clinically Oriented Anatomy: Testes*.
90. Morakinyo, A. O., Achema, P. U., & Adegoke, O. A. (2010). Effect of *Zingiber officinale* (Ginger) on sodium arsenite-induced reproductive toxicity in male rats. *African Journal of Biomedical Research*, 13(1), 39-45.
91. Moumen, R., Ait-Oukhatar, N., Bureau, F., Fleury, C., Bouglé, D., Arhan, P., ... & Viader, F. (2001). Aluminium increases xanthine oxidase activity and disturbs antioxidant status in the rat. *Journal of trace elements in medicine and biology*, 15(2-3), 89-93.
92. Nuhair, R. (2015). Effects of Aluminum chloride on some hormones levele and reproductive organs of male rats (*Rattus norvegicus*). *University of Thi-Qar Journal of Science*, 5(2), 3-9.
93. Okoro, V. M. O., Nwokeocha, A. C. C., Ijezie, C. O., Mbajiorgu, C. A., & Mbajiorgu, E. F. (2016). Effect of varying dietary supplemental inclusion levels of onion and garlic on semen quality characteristics of Hubbard white breeder broiler cocks aged 35-41 weeks old. *Indian Journal of Animal Research*, 50(6), 922-929.
94. Olah, G. A. (1963). *Friedel-Crafts and related reactions* (Vol. 1). Interscience Publishers.
95. Ola-Mudathir, K. F., & Maduagwu, E. N. (2014). Antioxidant effects of methanol extract of *Allium cepa* linn on cyanide-

- induced renal toxicity in male wistar Rats. *Nigerian Journal of Physiological Sciences*, 29(2), 147-151.
96. Olsson, M. E., Gustavsson, K. E., & Vagen, I. M. (2010). Quercetin and isorhamnetin in sweet and red cultivars of onion (*Allium cepa* L.) at harvest, after field curing, heat treatment, and storage. *Journal of agricultural and food chemistry*, 58(4), 2323-2330.
97. Oyewusi, J. A., Saba, A. B., & Olukunle, J. O. (2015). Phytochemical, elemental and acute toxic effects of methanol extract of onion (*Allium cepa*) bulbs in Wistar albino rats experimentally pre-exposed and rested for a week.
98. Peng, J. H. F., Xu, Z. C., Xu, Z. X., Parker, J. C., Friedlander, E. R., Tang, J. P., & Melethil, S. (1992). Aluminum-induced acute cholinergic neurotoxicity in rat. *Molecular and chemical neuropathology*, 17, 79-89.
99. Pizent B, Tariba T, and, Zivkovic. (1994). Reproductive toxicity of metals in men, Actions of aluminum on voltage-activated calcium channels currents. *Molecular Cell Neurobiology*.14:819-29.
100. Roberts, E. (1986). Alzheimer's disease may begin in the nose and may be caused by aluminosilicates. *Neurobiological Aging*; 7:561-567.
101. Salama A.F, Newairy A.S, Hussein H.M, & Yousef M.I. (2009). Propolis alleviates aluminium-induced lipid peroxidation and biochemical parameters in male rats. *Food and Chemical Toxicology*. 47(6):1093-8.
102. Salgado B.S, Monteiro L.N, and Rocha N.S. (2011). Allium species poisoning in dogs and cats. *Journal of Venomous Animals and Toxins Including Tropical Diseases*. 17 (1): 4-11.
103. Sample Ian. (2008). How many people have four kidneys? *The Guardian*. London.
104. Sembuligam K. and Sembuligam Prema. (2012). Essential of Medical Physiology. 6th Edition. Japee Brothers Medical Publishers LTD. Pp. 301-330.
105. Sera F.I, Samuel B. Olaleye, Roland E. A, et al. (2012). Testicular toxicity and sperm quality following cadmium exposure in rats: Ameliorative potentials of *Allium cepa*. *Journal of Human Reproductive Science*; 5(1): 37-42.
106. Shahraki M.R. Zahedi Asl S. and, Sarkaki A.R. (2004). The Effect of Aluminum Injection in Lateral Ventricle on Sex Hormones in Male Rat. *Shiraz E-Medical Journal*; 5(2) 1-10.
107. Sikka S.C, Rajasekaran M, and Hellstorm W.J. (1995). Role of oxidative stress and antioxidants in male infertility. *Journal of andrology*. 16(6):464-8.
108. Singh H.P, Singh C.K, Singh R.R. (1998). Effect of potash alum (aluminum potassium sulphate) on human semen and sperm. *Indian Journal of Physiology and Pharmacology*; 42:311-423.
109. Singh T, Goel. R.K. (2016). Neuroprotective effect of *Allium cepa* Linn in aluminum chloride induced neurotoxicity. *Journal of Neuro-Toxicology*;49: 1-7.
110. Slimestad R, Fossen T and Vågen I. M. (2007). Onions: A source of unique dietary flavonoids. *Journal of Agricultural and Food Chemistry*; 55 (25): 10067-80.
111. Smith, S. E. (2013). What is onion powder. *WiseGeek. Conjecture Corporation*. <https://www.wisegeek.com/what-is-onion-powder.htm> [6 January 2018].
112. Snider B.B. (1980). Lewis-acid catalyzed ene reactions". *Journal of chemical research*; 13 (11): 426.
113. Stella M. Nestor M, Marcela G.C. Maria Del Carmen and Maria Monica E. (2005) .Alterations of the renal function and oxidative stress in renal tissue from rats chronically Treated with aluminum during the initial phase of hepatic regeneration. *Journal of inorganic Biochemistry*. 99: 1858-1864.
114. Stepp J.R. (2004). The Role of Weeds as Source of Pharmaceuticals. *Journals of Ethnopharmacology* 92 (2-3): 163-166.
115. Strong M.J, and He B.P. (2000). A morphological analysis of the motor neuron degeneration and microglial reaction in acute and chronic in vivo aluminum chloride neurotoxicity. *Journal of Chemistry & Neuroanatomy*.17 (4): 207-15.
116. Suslov D, Verbelen J.P, and Vissenberg K. (2009). Onion epidermis as a new model to study the control of growth anisotropy in higher plants. *Journal of Experimental Botany*;60 (14): 4175-87.
117. Tahara, H. (2004). Osteomalacia and vitamin D deficiency in hemodialyzed patients. *Journal of Clinical Pharmacology*; 14:42-45.
118. Tapsell L.C, Hemphill I, and Cobiac L. (2006). Health benefits of herbs and spices: the past, the present, the future. *Journal of Clinical Medicine*. 185: S4-24.
119. Toxicological guide for aluminum (TGA). (2011). U.S. Department of human and public health service. *Journal of environmental medicine and applied toxicology*.13:141-9
120. Tse A, Tse F.W, Almers W, and Hill B. (1993). Rhythmic exocytosis stimulated GnRH-induced calcium oscillations in rats gonadotropes. *Andrology & Science*; 260:82-4.

121. Tse A, Tse FW, Almers W, Hill B. Rhythmic exocytosis stimulated GnRH-induced calcium oscillations in ratsgonadotropes. *Science*. 1993;260:82–4.
122. Turner R.M.O. (2007). Pathogenesis, diagnosis, and management of testicular degeneration in stallions. *Clinical and Technological Practice*; 6: 278–284.
123. Turner T.T and Lysiak J.L. (2008). Oxidative stress: A common factor in testicular dysfunctions. *Journal of Andrology*; 29: 488-498.
124. Verstraeten I. Aimo, and Oteiza P.I. (2008).Aluminum and lead: molecular mechanisms of brain toxicity. *Archives of toxicology*; 82: 789–802.
125. Walter F. Boron (2004). Medical Physiology: A Cellular And Molecular Approach. *Elsevier/Saunders* -4160-2328-3.
126. Ward R.J, Zhang Y, Crichton R.R. (2001). Aluminum toxicity and iron homeostasis, *Journal of Inorganic Biochemistry*. 879-14.
127. Wells A.F. (1984). Structural Inorganic Chemistry, Oxford Press, United Kingdom.
128. Wisconsin Food Safety and Health. (2012). Archived from the Original on 2012-12-24.
129. Xu K, Huang X, Wu M, Wang R, Tan G, *et al.* (2014). A rapid, highly efficient and Economical Method of Agrobacterium Mediated in Planta Transient Transformation in living Onion Epidermis. *Journal of Food Chemistry*; 9(1):1371.
130. Yakubu O. E, Nwodo O.F.C, Imo C and Ogwoni H. A. (2017) .Spermatogenic and Hematological effects of Aqueous and Ethanolic Extracts of *Hymenocardia acida* Stem Bark on Aluminum-Induced Toxicity in Male Wistar Rats. *Journal of industrial hygiene and toxicology*: 2(11-5) 35-46.
131. Yang C.Y, Chao P.D, Hou Y.C, Tsai S.Y, Wen K.C, Hsiu S.L. (2006). Marked decrease of cyclosporine bioavailability caused by co administration of ginkgo and onion in rats. *Journal of Food & Chemical*
132. Yokel R.A. (2000). The toxicology of Aluminium in brain. *Journal of Neurotoxicology* .21 (5): 813-828.
133. Yokel R.A. (2002).Brain uptake, retention, and efflux of aluminum and manganese, Environmental Health Perspectives. *Journal of Environmental Medicine*; 110: 699–704.
134. Yousef M.I, El-Morsy A.M.A, and Hassan M.S. (2005). Inhibition of steroidogenesis in Leydig cells by exogenous nitric oxide occurs independently of steroidogenic acute regulatory protein. *Journal of Toxicology*; 215: 97-107.
135. Yousef M.I, Kamel K.L, ElGuendi M.I, and El-Demerdash F.M. (2007). An in vitro study on reproductive toxicity of aluminum chloride on rabbit sperm: The protective role of some antioxidants. *Toxicology*; 239:213–23
136. Yousef,M.I. and Salama,A.F.(2009). Propolis protection from reproductive toxicity caused by aluminium chloride in male rats. *Food and Chemical Toxicology*; 47: 1168-1175.
137. Zohary D and Maria H. (2000). Domestication of plants in the Old World Oxford University Press. Pp. 198.
138. Zubenko G.S, and Hanin I. (1989). Cholinergic and noradrenergic toxicity of intraventricular aluminum chloride in the rat hippocampus. *Brain Reseaerch*. 498 (2): 381–4.